

## CASE REPORTS

# Cardiac headache in acute coronary syndrome

Phillip Tran<sup>\*1</sup>, Robert Ziffra<sup>2</sup>, Hoai V. Nguyen<sup>3</sup>, Selena M. Losee<sup>4</sup>

<sup>1</sup>Department of Cardiology, Mercy Medical Center, North Iowa, Mason City, United States

<sup>2</sup>Department of Medical Sciences, Dominican University, Chicago, United States

<sup>3</sup>Mercy Medical Center, Des Moines, United States

<sup>4</sup>Department of Internal Medicine, Des Moines University, Des Moines, United States

**Received:** January 13, 2017

**Accepted:** May 27, 2017

**Online Published:** June 12, 2017

**DOI:** 10.5430/crim.v4n3p21

**URL:** <https://doi.org/10.5430/crim.v4n3p21>

## ABSTRACT

Acute coronary syndrome may present in a wide distribution of symptoms. The classic presentation includes substernal chest pain, neck pain, dyspnea or syncope. In patients with coronary risk factors who present with headaches, acute coronary syndrome is rare, but has been previously reported. We describe a case of 63-year-old female who presented with a severe headache and developed a Non ST-Elevation Myocardial Infarction.

**Key Words:** Acute coronary syndrome, Atypical chest pain, Cardiac angiogram

## 1. INTRODUCTION

Acute coronary syndrome is a prevalent diagnosis of patients presenting to most Emergency Rooms across the United States. Clinical presentation of coronary ischemia typically involves pressure-like, substernal chest pain that radiates to the left arm and neck. Atypical presentations are more common in females, elderly and diabetics. A headache as the initial presentation of a myocardial infarction (MI) has rarely been described, but appears to be more characteristic of an anterior wall infarction. We present a case of a patient who presented initially with a severe headache and was found to be in acute coronary syndrome.

## 2. CASE PRESENTATION

We present the case of a 63-year-old female with a history of insulin dependent diabetes, hypertension, and hyperlipidemia that presented to the Emergency Room with a severe frontal headache. The headache was new onset, graded as severe, and without prodrome or without vision changes. The

patient also complained of severe typical angina lasting for over 24 hours and was eventually relieved with aspirin. Upon examination, the patient appeared fatigued but not in distress. The patient's vital signs demonstrated a blood pressure 134/62 mmHg, with a heart rate of 50 beats per minute. The patient was saturating 95% in room air. The patient was confused, oriented only to place. The rest of the patient's neurologic and ocular exams were unremarkable. The patient's heart sounds were irregular but no appreciable murmurs.

A non-contrast computerized tomography (CT) of the head was free of intracranial hemorrhage. The initial EKG demonstrated ST-depression and T-wave inversion over the anterior leads (see Figure 1). The patient's troponin was initially negative, but became elevated to a maximum of 7.11  $\mu\text{g/L}$ , giving the patient's diagnosis of Non-ST-Elevation Myocardial Infarction (NSTEMI). A 2-D Echocardiogram revealed a low-normal ejection fraction of 50%-55% without regional wall motion abnormalities. The patient was then started on

\*Correspondence: Phillip Tran; Email: [ptranynyit@gmail.com](mailto:ptranynyit@gmail.com); Address: Department of Cardiology, Mercy Medical Center, 1000 4th St SW, Mason City, IA 50401, United States.

medical therapy with aspirin, plavix, heparin, and a beta-blocker. Although the patient's chest pain had resolved, the patient continued to have intermittent headaches that were difficult to control with medication. Because of the patient's NSTEMI, the patient was taken to the cardiac catheterization lab where the patient was found to have severe coronary artery disease with proximal left anterior descending (LAD) of 65%, mid LAD of 60% to the distal LAD of 99% stenosis.

The patient's left circumflex showed a mid-circumflex 99%, and a proximal right coronary artery (RCA) of 30% and the right posterior descending artery (PDA) of 50%. (see Figure 2). Consideration was made for Coronary Artery Bypass Grafting versus multivessel Percutaneous Coronary Intervention (PCI). The patient ultimately opted for PCI, after which the patient's chest pain and headaches resolved. The patient was then discharged from the hospital.

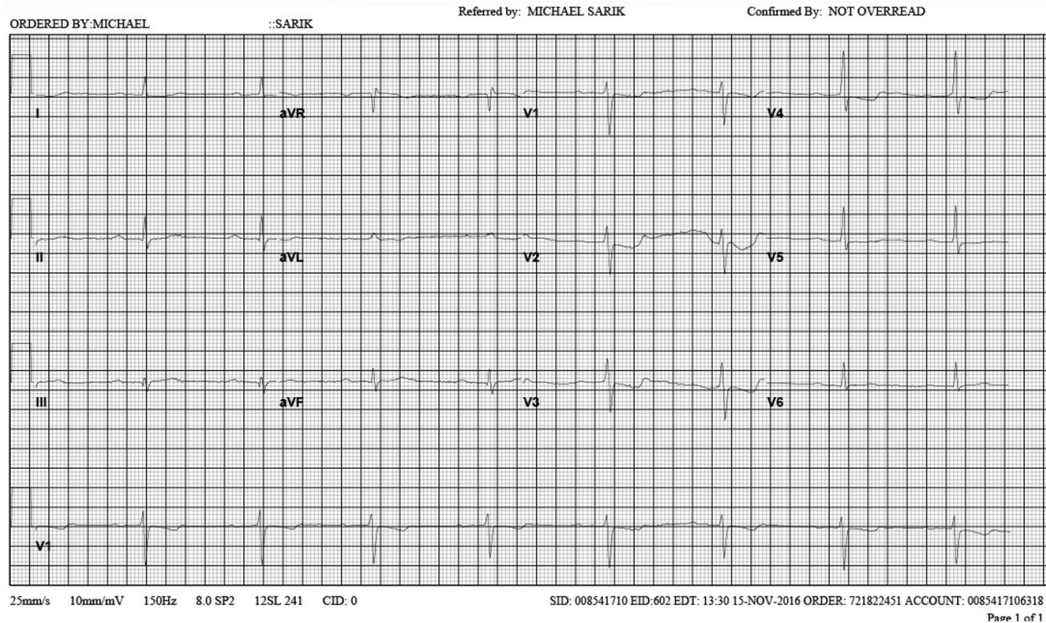


Figure 1. EKG showed ST-depression and T wave inversion over anterior leads V1-V4

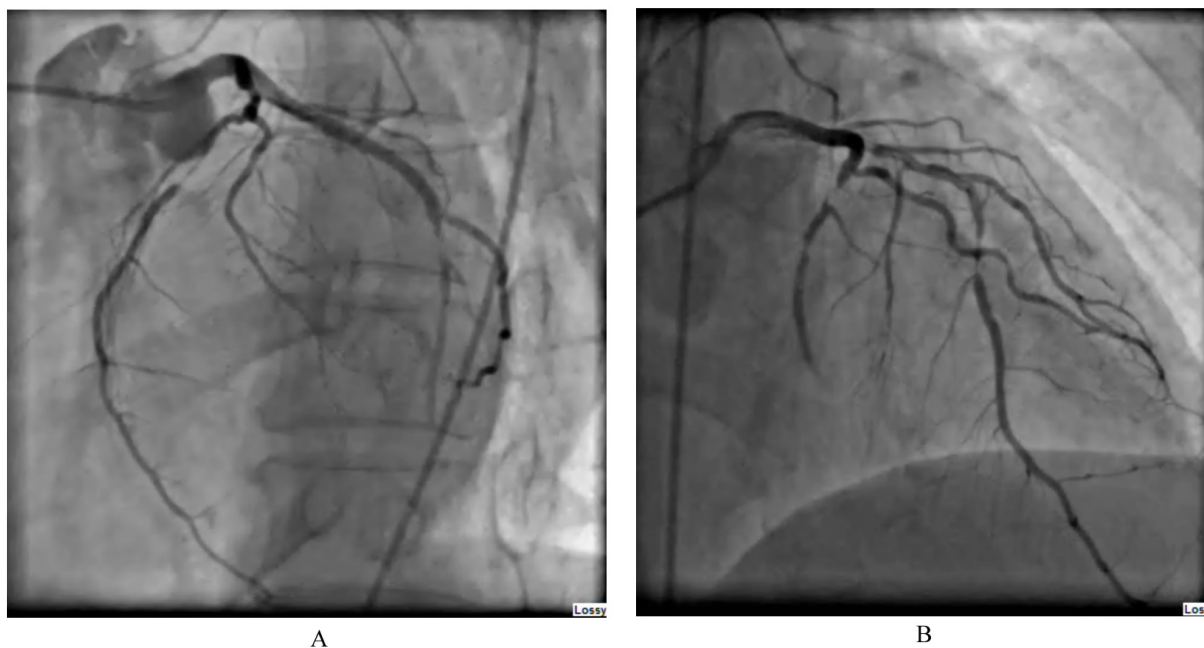


Figure 2. Urgent coronary angiogram showed severe coronary artery disease with proximal LAD of 65%, mid LAD of 60% to the distal LAD of 99% stenosis. The patient's left circumflex showed a mid-circumflex 99%.

### 3. DISCUSSION

In the United States, 780,000 patients present annually with acute coronary syndrome, 70% of which are diagnosed with Non ST-Elevation Myocardial Infarction (NSTEMI). NSTEMI is defined in patients with chest pain, elevated biomarkers, and transient or persisting ST depressions or T-wave inversions. The median age for acute coronary syndrome (ACS) in the United States is 68 years old. Acute coronary syndrome occurs when there is an imbalance between myocardial oxygen supply and demand, resulting in hypoxia and necrosis of the myocardium. This is often in the setting of a coronary lesion, low flow state, or high oxygen demand. The hallmark of ACS treatment is antiplatelet therapy and revascularization.<sup>[1]</sup> Classically, ACS presents as retrosternal pressure or tightness radiating to the left arm, but other symptoms may also occur including dyspnea, syncope, vertigo, and vomiting, among others. Female patients may present with less classic symptoms, while diabetics may even be asymptomatic due to polyneuropathies.

Several cases of patients with a chief complaint of a headache during an acute myocardial infarction have previously been described. Culic et al. report a retrospective study of 731 patients presenting with myocardial infarction. Anterior infarcts more frequently presented with headaches than other infarct territories.<sup>[2]</sup> In another case series of myocardial infarctions, 6% of patients presented with headache but most had other associated symptoms as well.<sup>[3]</sup> Other reports describe exertional headache, similar to exertional angina in patients with known CAD and myocardial infarctions.<sup>[4,5]</sup> Additional rare cases of patients presenting with headache as the sole symptom during myocardial infarction have been described primarily in elderly male patients, sometimes with initially normal EKG's.<sup>[6-10]</sup>

The pathophysiology behind headache symptomatology during acute myocardial infarction (MI) has yet to be clearly reported. Some proposed mechanisms include the crossing of cardiac sympathetic fibers with cranial pain afferent fibers from C1-C3, which could cause referral pain to the head during a myocardial infarction. Additionally, convergence of cardiac vagal afferents with the neurons in the trigeminal nucleus may refer pain during MI to any of the areas supplied by Cranial Nerve V, many of which give off sensations around the head.<sup>[11]</sup> A second hypothesis suggests that pro-inflammatory mediators (i.e. bradykinin, serotonin, histamine, and adenosine) released during the ischemic process of MI lead to vasodilation, which could in turn cause

headache much like nitroglycerin, with its vasodilatory properties, does.<sup>[12]</sup> This mechanism may warrant further review, as previous cases have shown nitroglycerin actually improves headaches during MI instead of making them worse. A final theory to describe this rare presentation of myocardial infarction claims that the reduction in cardiac output found in acute MI decreases venous return from the brain, which could cause increased intracranial pressure.<sup>[13]</sup> This may be unlikely, as MI hasn't been shown to cause increased intracranial pressure, although this theory would explain why these headaches seem to come about with exertion.

In the case we describe above, the patient is a 63-year-old female with CAD risk factors who developed a new onset: severe headache. The patient subsequently developed substernal chest pressure and developed a NSTEMI. On the angiogram, the patient was found to have severe multivessel coronary artery disease amenable to complex PCI. The patient's headache symptoms in conjunction with NSTEMI were consistent with previous cases reporting anterior wall myocardial infarction, which may have been the culprit vessel causing the patient's symptoms. Only after medical optimization and revascularization were the patient's headache symptoms resolved. The patient had risk factors for coronary artery disease and presented with a new onset severe headache, which warrants further workup. The patient's presenting headache, even without angina, may draw consideration for cardiac diagnostic workup including an EKG and cardiac biomarkers.

In conclusion, acute coronary syndrome is a prevalent diagnosis with various presentations. Less common presentations include headache, vertigo, epigastric pain, and sometimes no symptoms at all. Diagnosis of MI may be difficult in patients presenting solely with headache unless a high index of suspicion is kept. Furthermore, diagnosis may be delayed if a neurologic workup is prioritized. All patients reviewed with this rare presentation of MI had at least one cardiovascular risk factor. Some of the patients had no history of headache, while those that did have a history described this headache as very different. We conclude that it is reasonable to screen for acute coronary syndrome in patients who present with risk factors for coronary artery disease with atypical symptoms like those stated above, including severe headache in any location.

### CONFLICTS OF INTEREST DISCLOSURE

The authors have declared no conflicts of interest.

**REFERENCES**

- [1] Amsterdam EA. 2014 AHA/ACC Guideline for the Management of Patients With Non-ST-Elevation Acute Coronary Syndromes; 2014.
- [2] Čulić V, Mirić D, Eterović D. Correlation between symptomatology and site of acute myocardial infarction. *International Journal of Cardiology*. 2001; 77 (2): 163-8. [https://doi.org/10.1016/S0167-5273\(00\)00414-9](https://doi.org/10.1016/S0167-5273(00)00414-9)
- [3] Sampson JJ, Cheitlin MD. Pathophysiology and differential diagnosis of cardiac pain. *Progress in cardiovascular diseases*. 1971; 13(6): 507-31. [https://doi.org/10.1016/S0033-0620\(71\)80001-4](https://doi.org/10.1016/S0033-0620(71)80001-4)
- [4] Lipton RB, Lowenkopf T, Bajwa ZH, et al. Cardiac cephalgia: a treatable form of exertional headache. *Neurology*. 1997; 49 (3): 813-6. PMID:9305346 <https://doi.org/10.1212/WNL.49.3.813>
- [5] Olesen J. International Classification of Headache Disorders, (ICHD-2): Current status and future revisions. *Cephalalgia*. 2006; 26(12): 1409-10. PMID:17116090 <https://doi.org/10.1111/j.1468-2982.2006.01214.x>
- [6] Amendo MT, Brown BA, Kossow LB, et al. Headache as the sole presentation of acute myocardial infarction in two elderly patients. *The American Journal of Geriatric Cardiology*. 2001; 10(2): 100-1. PMID:11253457 <https://doi.org/10.1111/j.1076-7460.2001.00842.x>
- [7] Korantzopoulos P, Karanikis P, Pappa E, et al. Acute Non-ST-Elevation Myocardial Infarction Presented as Occipital Headache with Impaired Level of Consciousness A Case Report. *Angiology*. 2005; 56 (5): 627-30. PMID:16193204 <https://doi.org/10.1177/000331970505600516>
- [8] Wei JH, Wang HF. Cardiac cephalgia: Case reports and review. *Cephalalgia*. 2008; 28(8): 892-6. PMID:18505457 <https://doi.org/10.1111/j.1468-2982.2008.01590.x>
- [9] Elgharably Y, Iliescu C, Sdringola S, et al. Headache: A symptom of acute myocardial infarction; 2013.
- [10] Cutrer FM, Pac KH. Exertional headache and coronary ischemia despite normal electrocardiographic stress testing. *Headache: The Journal of Head and Face Pain*. 2006; 46(1): 165-7. PMID:16412165 [https://doi.org/10.1111/j.1526-4610.2006.00316\\_1.x](https://doi.org/10.1111/j.1526-4610.2006.00316_1.x)
- [11] Meller ST, Gebhart GF. A critical review of the afferent pathways and the potential chemical mediators involved in cardiac pain. *Neuroscience*. 1992; 48(3): 501-24. [https://doi.org/10.1016/0306-4522\(92\)90398-L](https://doi.org/10.1016/0306-4522(92)90398-L)
- [12] Guazzi M, Polese A, Fiorentini C, et al. Left and right heart haemodynamics during spontaneous angina pectoris. Comparison between angina with ST segment depression and angina with ST segment elevation. *British Heart Journal*. 1975; 37(4): 401-13. PMID:1125117 <https://doi.org/10.1136/hrt.37.4.401>
- [13] Ramadan NM. Headache caused by raised intracranial pressure and intracranial hypotension. *Current Opinion in Neurology*. 1996; 9(3): 214-8. PMID:8839614 <https://doi.org/10.1097/00019052-199606000-00011>