

CASE REPORTS

Paroxysmal nocturnal hemoglobinuria (PNH): An atypical case report

Luc Longrée¹, Renaud Roufousse¹, Stéphanie Maréchal¹, Julie Goffinet², Renaud Maquet³, Christian Focan*¹

¹Department of Onco-Hematology, CHC-Liège; Clinique Saint-Joseph, Liège, Belgium

²Clinical Biology Laboratory, CHC-Liège; Clinique Saint-Joseph, Liège, Belgium

³Department of Pharmacy, CHC-Liège; Clinique Saint-Joseph, Liège, Belgium

Received: December 23, 2017

Accepted: January 29, 2018

Online Published: February 9, 2018

DOI: 10.5430/crim.v5n1p39

URL: <https://doi.org/10.5430/crim.v5n1p39>

ABSTRACT

Introduction: Paroxysmal nocturnal hemoglobinuria (PNH) also called Marchiafava-Micheli syndrome is a rare disease (1.3 case per million individuals). It is a clonal disorder caused by a medullary stem cells acquired mutations on the *PIG-A* gene, inducing a partial or general deficit of proteins linking to cell membrane through a glycoposphatidylinositol (*GPI*) anchor.

Case presentation: We confirmed the diagnosis of PNH in a 35-year-old woman presenting a relatively well tolerated but progressive pancytopenia and also a concomitant cyanocobalamin deficiency. The diagnosis was classically obtained through flow cytometry determination of specific disease markers on red blood cells (CD55; CD59; FLAER). After a CD34 selected grafting from his fully HLA-compatible brother as donor, the patient entered in a sustained complete remission of PNH syndrome.

Conclusion: After bone-marrow grafting, prolonged complete remission (cure) of PNH presenting primarily as a medullary insufficiency, may be obtained.

Key Words: Paroxysmal nocturnal hemoglobinuria, Medullary aplasia, Allograft

1. INTRODUCTION

Paroxysmal nocturnal hemoglobinuria (PNH) characterized by “dark nocturnal urines” has been first observed by the end of XIXth century and further better described by Marchiafava and Micheli in 1931.^[1] This is a rare disease (1.3 cases per million individuals) expressed predominantly in young (median age 32) caucasian people. Recent studies have shown that the disease was related to an acquired mutation of hematopoietic stem cell on phosphatidyl-inositol glycan (*GPI*) class A (*PIG-A*) gene located on X chromosome.^[2-6] This mutation will lead to a partial or complete failure of proteins linked to cell membrane through a glycoposphatidylinositol (*GPI*) anchor.^[2-6] We report the case

of a young woman whose initial presentation was atypical. The diagnosis was difficult because of concomitant cyanocobalamin (B12 vitamin) deficiency. She entered in a sustained complete remission of disease after allogenic bone marrow grafting.

2. CASE PRESENTATION

Mrs J.V born on April 3rd 1978 was seen in the out patient clinic on April 29th 2013. Her previous history was characterized by psycho-functional problems while in 2001, she underwent a laparoscopic gastroplasty for morbid obesity. She complained from fatigue, dyspnea and occasional palpitations. There was no familial history of hematologi-

*Correspondence: Christian Focan; Email: christian.focan@chc.be; Address: Oncology Department, Clinique Saint-Joseph; rue de Hesbaye, 75; B-4000-Liège, Belgium.

cal disorders. Medications were: amitriptyline, alprazolam, tetrazepam and prothipendyl. Clinical examination and general biology were normal but hematological parameters revealed pancytopenia and macrocytosis initially attributed to a effective cyanocobalamin (B12 vitamin) deficiency (see Table 1). Serum iron, ferritin, LDH and reticulocytes titrations remained within normal range as well as Coombs erythrocytes test with absence of circulating schizocytes. However haptoglobin level was broken down from onset. Despite a correction of B12 levels from repeated parenteral administrations, hematological parameters did not improve while patient mentioned the occurrence of dark nocturnal urines. Thus a bone marrow examination was performed on May 15th 2013. Megaloblastic cells were seen on red lineage with enlargement and irregularities of cytoplasm, nuclear

abnormalities in pearl chromatin and Jolly bodies. White lineage was diminished with a right deviation and some nuclear alterations. Lympho-plasmocytosis was also increased due in a context of relative medullary hypoplasia (see Figure 1). The medullary hypoplasia with right deviation of red and granulocytic lineages and reactional lympho-plasmocytosis was confirmed by a second analysis on June 19th 2013 (see Figure 2). Prussian Blue coloration did not show ringed sideroblasts and there was no evidence for a myelodysplastic syndrome. Karyotyping was normal. The diagnosis of PNH was confirmed by flow cytometry determinations of specific PNH markers CD55, CD59 and aerolysin.^[2-6] A small *GPI*-deficient clone of 7% in circulating blood and 19% on medullary cells was notified.

Table 1. Hematological parameters

Variables; Units	Normal values	Pre Allograft		Graft	Post Allograft		
		2013/4/8	2013/9/11	2013/11/14	2014/5/5	2014/12/2	2015/9/29
Hb; g%	12.0-16.0	7.6	8	9	11.1	11.6	12.2
Hematocrite; %	37-47	23	24	28	31.8	36	37.2
Erythrocytes; million/mm ³	4.1-5.4	1.97	2.33	2.64	3.42	3.7	4.05
MCV; microns cube	80-100	116.7	103	106	93	97.3	91.9
MCH; pgr	26-32	38.5	34	34	32.5	31.4	30.1
Leucocytes	4-9 * 1,000	2	2.5	2.6	5.94	4.05	4.82
Neutrophiles %	50-70	54	32.6	68.2	74.2	53.8	55.2
Platelest; * 1,000/mm ³	150-400	72	66	86	385	321	295
Serum iron; microgr/dl	37-145	129	157		48	302	100
Ferritin; microgr/L	10-291	156	175				
Vit B12; ng/L	211-911	121	239				
Haptoglobin; gr/L	0.56-3.2	0.02					
LDH; U/L	< 480	386	380	361	173	209	153

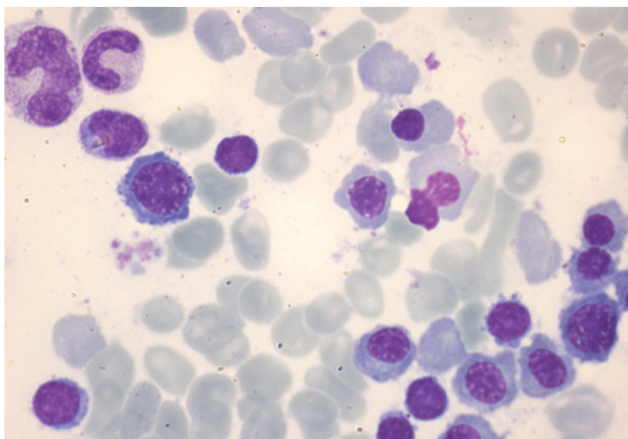


Figure 1. Medullary sample (15-5-2013); poor bone marrow; note a giant metamyelocyte and megaloblastic normoblasts with nuclear abnormalities (Hematoxylin-Eosin colouring; magnification 500×)

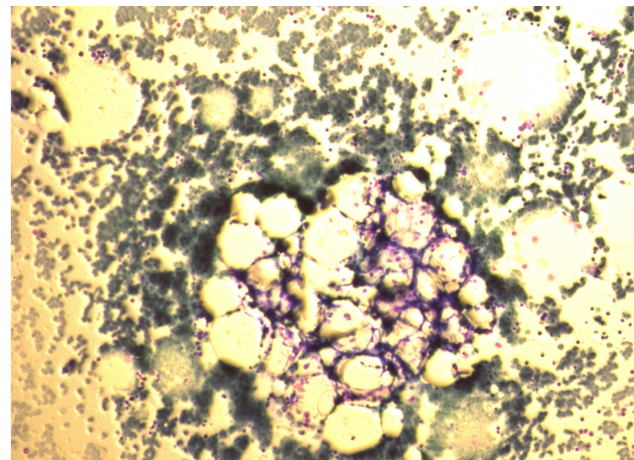


Figure 2. Bone marrow sample (19-6-2013). Compatible with a medullary aplasia (May-Grünwald-Giemsa colouring; magnification 200×).

Considering the importance of bone marrow failure, the therapeutic choice was oriented towards an allogenic bone marrow grafting. Thanks to a perfect HLA-compatibility between the patient and her brother, she could undergo, after some support transfusions, a selected CD34 allograft on November 22th 2013 in the Unity of Medullary Transplantation of the CHU-Sart-Tilman (University of Liège; Belgium; Professor Yves Beguin). Tolerance to the procedure was simple, just shadowed with an episode of fever with cutaneous rash and 2 episodes of *Clostridium difficile* colitis. An acute renal failure attributed to toxicity of tacrolimus was also quickly resolute.

During follow-up, a poor medullary and lymphocytic chimerism but a clear improvement of pancytopenia and a progressive disappearance of *GPI*-deficient clone (undetectable from november 2014) were ascertained. Cyanocobalamin deficiency definitively attributed to previous gastropasty had to be corrected with monthly injections. Despite a limited therapeutic compliance to post-grafting medications (tacrolimus, aciclovir, co-trimoxazole) a progressive weaning from march 2015 and even a complete withdrawal of tacrolimus from may 26th 2015 were possible. Hematological assessment remained normal from September 29th 2015 until now (October 10th 2017).

3. DISCUSSION

On the contrary to other intrinsic abnormalities of erythrocyte, PNH is a rare acquired mutation of hematopoietic stem cell. This mutation is located on X chromosome at the level of phosphatidyl-inositol glycan (*GPI*) class A gene.^[2-6] This gene is required for *GPI* synthesis, a glycolipid derivative necessary to anchor number of proteins to cell surface.^[3-5] Thus descending cells from affected stem cells (erythrocytes, granulocytes, platelets, monocytes and lymphocytes) will be deficient for all *GPI*-anchored proteins.^[2-6] Among twenty deficient proteins, DAF (decay accelerating factor) or CD 55 and MIRL (membrane inhibitor of reactive lysis) or CD 59, both primary regulators of complement at the level of erythrocyte membrane will be of peculiar interest.^[2-6] In fact their lowering will refer to intravascular complement mediated hemolysis, one of the 3 key symptoms of the disease.^[2-6] Effectively the frequency of hemolytic crises is in direct relation to PGI clone size and LDH serum levels. Eculizumab (Eculizumab ; Solirix R, Alexion Pharmaceuticals),^[6-9] a humanized monoclonal antibody recently developed is able to block specifically terminal activation of the complement cascade at the C5 level. Prevention of C5 clivage will block C5a induction, a pro-inflammatory molecule, and C5b, initial substrate for erythrocytes cell membrane attacking complexes. Despite individual variations, eculizumab will improve pa-

tients quality of life by reducing almost completely intravascular hemolysis.^[7-9]

Actual diagnosis of PNH, relies on flow cytometry determination of CD55 and CD59 markers at the erythrocyte membrane. Another interesting marker is the FLAER (fluorescent-labeled proaerolysin). Aerolysin, the principal virulence factor of aeromonas hydrophilic bacteria, is secreted as an inert protein, proto-aerolysin, which present a specific affinity for *GPI*-anchor; thus absence of its expression is pathognomonic of the presence of a *GPI*-deficient clone.^[2-6] For our patient, these 3 markers were confirmed positive at the blood and bone marrow levels.

The second usual symptom of PNH is characterized thrombophilia.^[1-6] Various mechanisms have been evoked to explain its physio-pathology. It seems that continuous activation of complement at the platelets surface will produce release of thrombinogen particules enriched in phosphatidylserine which can fix factor V and prothrombinase complexes.^[5,6] On another hand, intravascular hemolysis will exert a direct toxicity on endothelial cells membrane.^[3,5,10] These will release Willebrand and VIII factors and express inhibitors of tissular factor and plasminogen activator.^[6-9]

A third component of the PNH syndrome tripod is medullary insufficiency, affecting 48% of patients.^[3,5,10] Its physiopathology seems to be complex, 2 phenomenons being necessary to obtain bone marrow aplasia.^[3,5,10] In fact, PIG-A mutation will select PNH stem cells but it will be unable per se to favour their expansion; this last figure will be mediated through micro-environment auto or- dysimmunity.^[3,5,10,11] In other respects, oligoclonal T proliferation and apoptosis resistance of lymphocytes in proportion to PIG-A mutated stem cells levels have been evidenced.^[5,10]

For our patient, thrombotic accidents were absent. Hemolysis was moderate (normal LDH levels), thus eculizumab was not retained, as targeted monoclonal antibody.^[6-10] In fact clinical presentation was dominated by a progressive medullary failure requiring some transfusional supports before allograft.

The French Hematological Society has reported a significant improvement of PNH survival along time.^[3] If in 1996 the median survival was 14.6 years, in 2008 it attained 22 years.^[2] The factors of reduced survival were: diagnosis before 1996; age over 40; no treatment during first year; progression towards a bi- or pancytopenia; supervening of thrombotic complications and rare (4%) evolution to myelodysplastic syndrome or acute leukemia^[2] . Allogenic bone marrow grafting is the only curative treatment of PNH with a success varying from 50% to 70%.^[12] A non myeloablative

regimen is preferable in young people wishing to preserve their fertility.^[12] In the case of our patient, a complete sustained remission of PNH disease has been obtained with the administered therapy.

4. CONCLUSION

We had the privilege to diagnose a Marchiafava-Micheli syndrome or PNH in a young woman. The diagnosis was obtained after search for specific markers of the disease as the

clinical presentation was initially dominated by vitamin B12 deficiency. Medullary deficiency being ultimately the principal symptom, a selected CD34 fully compatible allograft allowed obtention of a complete remission of affection with progressive disappearance of PNH clone and thus potential clinical cure.

CONFLICTS OF INTEREST DISCLOSURE

The authors declare no conflicts of interest.

REFERENCES

- [1] Parker CJ. Paroxysmal nocturnal hemoglobinuria: an historical overview. *Hematology Am Soc Hematol Educ Program*. 2008; 1: 93-103. <https://doi.org/10.1182/asheducation.2008.1.93>
- [2] Parker CJ. Update on the diagnosis and management of paroxysmal nocturnal hemoglobinuria. *Hematology Am Soc Hematol Educ Program*. 2016; 1: 208-216. <https://doi.org/10.1182/asheducation-2016.1.208>
- [3] Peffaut de Latour R, Mary JY, Salanoubat C, et al. Paroxysmal nocturnal hemoglobinuria natural history of disease subcategories. *Blood*. 2008; 112(8): 3099-106. <https://doi.org/10.1182/blood-2008-01-133918>
- [4] Verreddy P. Hemoglobinuria misidentified as hematuria: review of discolored urine and paroxysmal nocturnal hemoglobinuria. *Clinical medical insights: Blood Disorders*. 2013; 6: 7-17. <https://doi.org/10.4137/CMBD.S11517>
- [5] Devalet B, Mullier F, Chatelain B, et al. Pathophysiology, diagnosis and treatment of paroxysmal nocturnal hemoglobinuria: a review. *Europ J Haematol*. 2015; 95(3): 190-8. <https://doi.org/10.1111/ejh12543>
- [6] Luzzatto L. Recent advances in the pathogenesis and treatment of paroxysmal nocturnal hemoglobinuria. *F1000Research*. 2016; 5(F1000 Faculty Rev): 209. <https://doi.org/10.12688/11000research.7288.1>
- [7] Hillmen P, Young NS, Schubert J, et al. The complement inhibitor eculizumab in paroxysmal nocturnal hemoglobinuria. *N Engl J Med*. 2006; 355(12): 1233-43. PMID:16990386. <https://doi.org/10.1056/NEJMoa061648>
- [8] Brodsky RA, Young NS, Antonioli E, et al. Multicenter phase 3 study of the complement inhibitor eculizumab for the treatment of patients with paroxysmal nocturnal hemoglobinuria. *Blood*. 2008; 111: 1840-7. PMID:18055865. <https://doi.org/10.1182/blood-2007-06-094136>
- [9] Al-Ani F, Chin-Yee I, Lazo-Langner A. Eculizumab in the management of paroxysmal nocturnal hemoglobinuria: patient selection and special considerations. *Ther Clin Risk Manag*. 2016; 12: 1161-70. PMID:27536121. <https://doi.org/10.2147/TCRM.S96720>
- [10] Griffin M, Munir T. Management of thrombosis in paroxysmal nocturnal hemoglobinuria: a clinician's guide. *Ther Adv Hematol*. 2017; 8(3): 119-126. <https://doi.org/10.1177/2040620716681748>
- [11] Ishiyama K. Immune pathophysiology of acquired aplastic anemia. *Rinsho Ketsueki*. 2016; 57(5): 525-30. <https://doi.org/10.11406/rinketsu.57.525>
- [12] Brodsky RA. Stem cell transplantation for paroxysmal nocturnal hemoglobinuria. *Haematologica*. 2010; 95(6): 855-6. <https://doi.org/10.3324/haematol.2010.023176>