

CASE REPORT

Strongyloidiasis infestation in a non-endemic area

MB Monereo-Muñoz ¹, E González-Reimers ¹, Álvavez-Argüelles H ², Martín-Ponce E ¹,
Pérez-Ramírez A ¹, González-Pérez.JM ¹, Jorge Ripper C ¹, García-Hernández S ²,
Hernández-González I ³

1. Servicio de Medicina Interna del Hospital Universitario de Canarias, La Laguna, Tenerife (Canary Islands), Spain. 2. Servicio de Anatomía Patológica del Hospital Universitario de Canarias, La Laguna, Tenerife (Canary Islands), Spain. 3. Servicio de Radiodiagnóstico del Hospital Universitario de Canarias, La Laguna, Tenerife (Canary Islands), Spain.

Correspondence: E González Reimers. Address: Ctra. Ofra, s/n, 38320 San Cristóbal de La Laguna, Santa Cruz de Tenerife, Spain. Email: egonrey@ull.es

Received: February 6, 2014

Accepted: April 11, 2014

Online Published: May 9, 2014

DOI: 10.5430/crim.v1n2p106

URL: <http://dx.doi.org/10.5430/crim.v1n2p106>

Abstract

Strongyloides stercoralis may reside in the intestinal wall asymptotically for decades and flare up when immunosuppression ensues. We report the case of a patient with hypereosinophilia of unknown origin in whom systemic strongyloidiasis was diagnosed after a course of steroids. The disease presented with recurrent meningitis and duodenal obstruction, and was treated uneventfully with Ivermectine. Probably the parasite was acquired during his stay in Venezuela twenty-seven years before.

Key words

Systemic strongyloidiasis, Hypereosinophilia, Recurrent meningitis, Duodenal obstruction

1 Introduction

Strongyloidiasis is a common parasitic infestation in tropical and subtropical areas of the world ^[1]. The parasite has a life cycle which allows a long-term survival in the host, without clinical manifestations. Indeed, in many cases infestation is asymptomatic. However sometimes patients may present episodic itching and rash, abdominal pain, nausea, vomiting, anorexia and diarrhoea, or respiratory alterations, such as asthma, cough or respiratory distress ^[2] accompanied by peripheral eosinophilia. Diagnosis may be elusive, since, frequently, fecal parasite investigation is negative ^[3].

Hypereosinophilia (eosinophils' count up to 500/ μ l) ^[4] may be present in these patients. Hypereosinophilia in the absence of an etiologic factor, such as asthma, autoimmune disease, especially Churg-Strauss, allergic reaction, malignancy ^[4], is called idiopathic hypereosinophilia (see Table 1). In this setting it is important to disclose the presence of myeloid leukaemia (especially when eosinophils are over 1000/ μ l), which usually presents the FIP1LI gene, or acute lymphoblastic leukemia ^[5]. In the absence of these entities, a pure idiopathic acquired hypereosinophilic syndrome should be placed on corticosteroids. However long-term steroid treatment may lead to immunosuppression, a condition which may favour proliferation of parasites such as *Strongyloides*. This is the mechanism by which severe systemic Strongyloidiasis have been described in patients with systemic lupus, rheumatoid arthritis and other diseases treated with steroids, usually with a very poor prognosis. Indeed, mortality reaches 80% ^[6].

We here report the case of the patient affected by systemic Stongyloidiasis which flared up during the course of steroid therapy for hypereosinophilia.

Table 1. Common Causes of hypereosinophilia

Allergic reactions	Drugs (acetylsalicylic acid, ACE* inhibitors sulfamides, penicilins, cephalosporins and nitrofurantoin)
Collagen diseases	Diseases(asthma, eczema, pemphigus, hay fever, serum sickness, allergic vasculitis)
Malignancy	Rheumatoid arthritis, eosinophilic fasciitis, Churg-Strauss disease
Parasitosis	Hodgkin disease, chronic myeloid leukaemia, lung, stomach, pancreas, uterine or ovarian cancer
Others	Addison disease, HIV infeccion,
Idiopathic	

* ACE= angiotensin converting enzyme

2 Case presentation

A sixty-eight-year-old man was seen as outpatient at the Internal Medicine Unit of our Hospital complaining vague systemic symptoms and subtle weight loss during the last two months. Physical examination was normal; plain X-ray film of the thorax was normal, and laboratory evaluation was also normal, besides a marked increase in eosinophils count (up to 2200/ μ l). Three parasite stool determinations were negative. After investigation of other causes of eosinophilia, no etiologic factor was found, and stool cultures and FIP1LI gene were negative. The patient was diagnosed of idiopathic hypereosinophilic syndrome and started with steroid treatment and Trimetoprim-Sulfametoxazol three times per week as prophylaxis.

Six months later the patient was admitted to the hospital because of headache and palilalia during the last twelve hours. The physical examination was normal, the blood test showed leukocytosis and neutrophilia. Haemoglobin, platelets, hepatic and renal functions were normal. The lumbar puncture was compatible with bacterial meningitis. Cerebrospinal fluid and blood culture were positive to *Streptococcus gallolyticus*. In the following two months the patient was admitted to our unit 2 times more, affected by two further episodes of meningitis (see Table 2) which were treated successfully with antibiotics. A CT brain scan and a magnetic resonance of the medulla were normal.

Table 2. Cerebrospinal fluid characteristics.

Meningitis	Leukocytes/mm ³	Neutrophiles %	Proteins (mg/dl)	Glucose mg/dL
First	8.000	95	>300	<20
Second	7.200	90	280	34
Third	2.500	85	231	20

After the third meningitis he started with abdominal pain and vomiting, mimicking a gastric outlet obstruction syndrome. A CT scan of the abdomen revealed gastric and duodenal edema and pyloric obstruction by a duodenal-dependent mass. A gastroscopic examination was performed, and a biopsy of a mass obstructing the pylorus revealed the presence of many

Strongyloides stercoralis (see Figures 1-4). *Strongyloides* was also isolated from sputum and gastric fluid. The patient was treated with ivermectine, with progressive improvement of his general status.

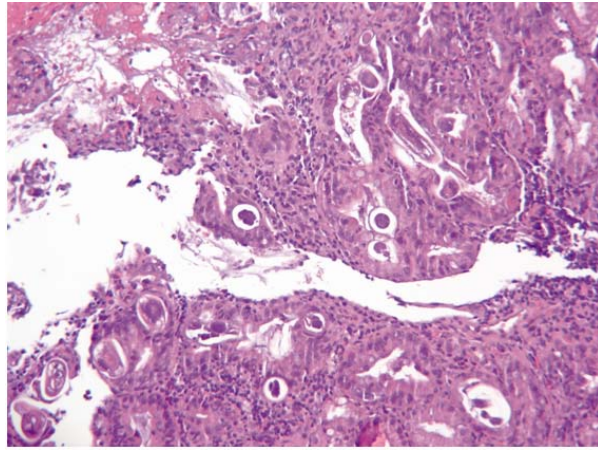


Figure 1. Duodenal mucosa with chronic inflammatory infiltrate (Haematoxylin-Eosin 100X), with structures parasite worms in criptae.

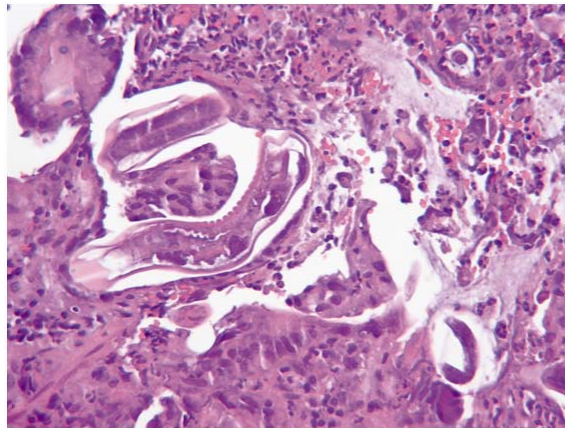


Figure 2. Adult parasites and larvae of *Strongyloides stercoralis* (Haematoxylin-Eosin 400X)

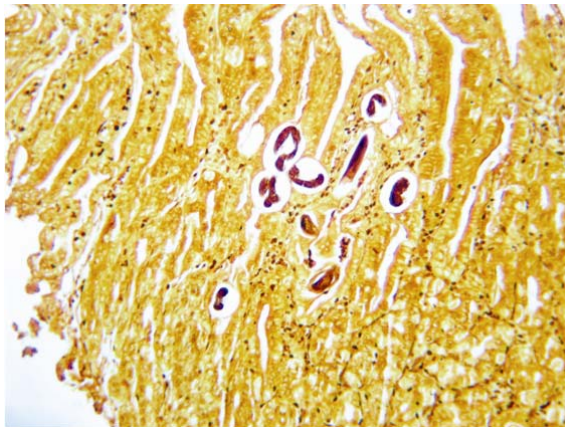


Figure 3. Gastric mucosa with numerous parasites (*Strongyloides stercoralis*) (Warthin-Starry 100X)

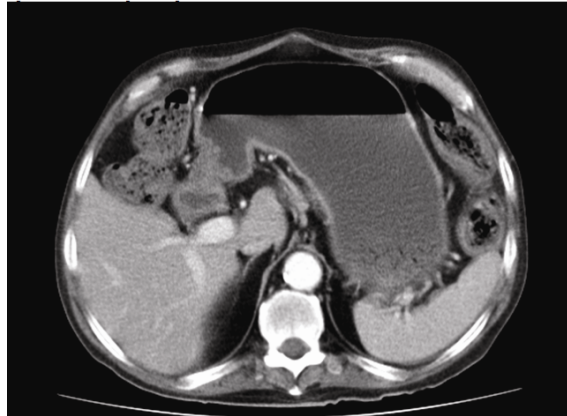


Figure 4. CT scan showing extreme gastric dilatation and an antral mass.

3 Discussion

As commented before systemic Strongyloidiasis is a very severe illness associated with high mortality. The parasite may live in intestinal submucosa for decades [7] and only occasionally may migrate to the intestinal lumen, where it becomes laden with intestinal bacteria. Bacteria-laden parasites may eventually gain the portal venous system and reach remote organs [8]. Indeed recurrent meningitis, usually due to Gram negative bacteria is a well described complication of systemic strongyloidiasis [9,10]. In fact this was the case of our patient in whom an unusual pathogen was isolated. Although liquid culture was negative in the other two episodes, meningitis were treated with Carbapenems and Vancomycin-wide-spectrum antibiotics covering both Gram positive and negative bacteria.

The diagnosis could be finally assessed by a biopsy specimen of a gastric mass in which many parasites were identified. In contrast with meningitis, duodenal obstruction by *Strongyloides* is not frequently observed [8,11]. This case constitutes a true diagnostic challenge, since in the Canary Island there is no Strongyloidiasis. In this sense this patient had been living in Venezuela for several years but had returned to the Islands twenty-seven years ago. We have to assume that the patient was infected by *Strongyloides* by the time he spent in Venezuela where the parasite is highly common and usually contaminates soil, drinking water and edible products. Long-term survival of *Strongyloides* within the intestinal mucosa causing no or little complain to the patient may be a potentially dangerous setting. Indeed, hypereosinophilia is a usual consequence of such an infestation and as commented previously hypereosinophilia may be labelled as idiopathic hypereosinophilic syndrome if eosinophils count increases over 1000/ μl , fecal examination is negative and no other cause of eosinophilia is identified. Hypereosinophilia per se may be associated with considerable morbidity and mortality (Löeffler pneumonia, endocardial elastosis, polyneuropathy...), so it must be treated with immunosuppressors, including corticosteroids, which in turn may exacerbate a latent parasite infestation.

Currently, serologic tests yield a higher diagnostic accuracy than in the past. The case here presented dramatically illustrates the convenience of performing such a test in the face of sustained hypereosinophilia, especially if the patient refers a travel history to regions in which Strongyloidiasis is endemic, even when a long time has elapsed between living in the endemic region and clinical presentation. However, it is important to keep in mind that up to 18% of cases remained undetected even with the classic serologic tests (sensitivity = 83%-95%), which also show a high rate of false positive results [7]. Fortunately, in recent times a luciferase immunoprecipitation assay markedly improves diagnostic yield [12].

In summary the case here presented illustrates the multiple, protean, manifestations of systemic strongyloidiasis, and the necessity of performing repeated fecal tests searching for *Strongyloides*, as well as serologic tests with high sensitivity in any patient with eosinophilia who requires steroids or immunosuppressive therapy, even in non-endemic areas of the world.

Conflict of interests

The authors have declared no conflicts of interest.

References

- [1] Chacín-Bonilla L. Estrongiloidiasis sistémica. Revisión. *Invest Clin*. 1991; 32(3): 131-145.
- [2] Becker SL, Sieto B, Silué KD, Adjossan L, Koné S, Hatz C, et al. Diagnosis, Clinical Features, and Self-Reported Morbidity of *Strongyloides stercoralis* and Hookworm Infection in a Co-Endemic Setting. *PLoS Negl Trop Dis*. 2011; 5(8): e1292. <http://dx.doi.org/10.1371/journal.pntd.0001292>
- [3] Krolewiecki AJ, Lammie P, Jacobson J, Gabrielli A, Levecke B, Socias E, et al. A Public Health Response against *Strongyloides stercoralis*: Time to Look at Soil-Transmitted Helminthiasis in Full. *PLoS Negl Trop Dis*. 2013; 7(5): e2165. <http://dx.doi.org/10.1371/journal.pntd.0002165>
- [4] Ogbogu PU, Bochner BS, Butterfield JH, Gleich GJ, Huss-Marp J, Kahn JE, et al. Hypereosinophilic syndrome: a multicenter, retrospective analysis of clinical characteristics and response to therapy. *J Allergy Clin Immunol*. 2009; 124: 1319. <http://dx.doi.org/10.1016/j.jaci.2009.09.022>
- [5] Roufousse F, Cogan E, Goldman M. Lymphocytic variant hypereosinophilic syndromes. *Immunol Allergy Clin North Am*. 2007; 27: 389-413. <http://dx.doi.org/10.1016/j.iac.2007.07.002>
- [6] Beduino F, Vada J, Miliotto E, Wulfsohn M, Fiorili F, Sacnum M, et al. *Strongyloides stercoralis*: manifestaciones sistémicas de la parasitosis. *Revista Argentina de Reumatología*. 2010; 21: 37-43
- [7] Ugarte-Torres A, Ñamendys-Silva S, Posadas-Calleja JG, Pedroza-Granados J, Domínguez-Cherit G. Estrongiloidiasis diseminada con presentación de abdomen agudo en una paciente con lupus eritematoso sistémico. Reporte de un caso y revisión de la literatura. *Neumología y Cirugía de Tórax*. 2006; 65: 146-149.
- [8] Mejía R, Nutman TB. Screening, prevention, and treatment for hyperinfection syndrome and disseminated infections caused by *Strongyloides stercoralis*. *Curr Opin Infect Dis*. 2012; 25: 458-463. <http://dx.doi.org/10.1097/QCO.0b013e3283551dbd>
- [9] Pérez F, Núñez F, Martín N, Cabrera R, Rodríguez E. Falla orgánica múltiple por estrongiloidiasis diseminada. Comunicación de un caso. *Rev Chilena Infectol*. 2012; 29: 344-347. <http://dx.doi.org/10.4067/S0716-10182012000300016>
- [10] Escobar RR, Mosquera EY. Strongiloidiasis pulmonar en inmunosupresión por esteroides sistémicos. Presentación de un caso. *Revista Colombiana de Neumología*. 2012; 18: 34-38.
- [11] Cruz Jr RJ, Vincenzi R, Ketzer BM. Duodenal obstruction - an unusual presentation of *Strongyloides stercoralis* enteritis: a case report. *World Journal of Emergency Surgery*. 2010; 5: 23. <http://dx.doi.org/10.1186/1749-7922-5-23>
- [12] Ramanathan R, Burbelo PD, Groot S, Iadarola MJ, Neva FA, and Nutman TB. A Luciferase Immunoprecipitation Systems Assay Enhances the Sensitivity and Specificity of Diagnosis of *Strongyloides stercoralis* Infection. *J Infect Dis*. 2008; 198: 444-451. <http://dx.doi.org/10.1086/589718>