

CASE REPORT

Intrathoracic Nocardia-abscess as a cause of haemodynamic instability

A. A. E de Joode ¹, W. L. Manson ², W. J. van Son ¹

1. Department of Internal Medicine, University Medical Center Groningen, Groningen, the Netherlands. 2. Department of Medical Microbiology, University Medical Center Groningen, Groningen, the Netherlands.

Correspondence: Anoeck A. E de Joode. Address: Department of Internal Medicine, University Medical Center Groningen, Hanzeplein 1, 9700 RB, Groningen, the Netherlands. Email: a.a.e.joode@umcg.nl

Received: February 25, 2014

Accepted: June 16, 2014

Online Published: June 26, 2014

DOI: 10.5430/crim.v1n2p195

URL: <http://dx.doi.org/10.5430/crim.v1n2p195>

Abstract

A 64-year old patient was admitted to our hospital one year after renal transplantation. He complained about headache, cough and fever. Blood cultures revealed *Nocardia nova*. Because of disseminated disease, he was treated with both co-trimoxazol and meropenem. Eight days later, his condition worsened. A CT-thorax was performed which showed large mediastinal masses and compression of vena cava superior and right atrium. The same evening, he underwent a thoracotomy because of haemodynamic instability. The aspirated pus again showed *Nocardia nova*. He recovered but developed pleural effusion and again this was positive for *Nocardia nova*. Both meronem and co-trimoxazol were continued. Six months after diagnosis, he was admitted because of gastro-intestinal bleeding and a mycobacterium species was found in gastric and duodenal biopsies. He was started on claritromycine and myambutol, but developed renal failure. Ten months after diagnosis of disseminated Nocardiosis, he died because of worsening condition and renal failure. No post-mortem examination was performed.

Revision of literature showed no other reports of hemodynamic instability by *Nocardia*-abscesses or compression on vena cava or right atrium.

Keywords

Nocardiosis, Renal transplantation, *Nocardia* abscess, Mediastinal masses

1 Introduction

Nocardia spp is a ubiquitous gram positive bacteria, which causes localised or disseminated diseases, especially in the immunocompromised. It is an infrequent infection, but incidence is rising, partly due to an increase in immunosuppressed patients for example after transplantation. Nocardiosis occurs worldwide: the incidence might be underestimated because of nonspecific complaints and delay in diagnosis can easily occur. This is worsening the prognosis for an illness that already has a high mortality rate.

2 Case report

A 64-year-old patient was admitted one year after non-heart-beating kidney transplantation because of worsening kidney function without evident cause. His medical history revealed haemodialysis and PCI after myocardial posterior infarction. The latest echocardiogram showed an aortic valve stenosis, gradient 36mmHg.

At the time of admission, he still used a triple immunosuppressive regimen -prednisone 10 mg a day, tacrolimus (3-6 u/l) and mycophenolate mofetil-; he also used metoprolol, diuretics, monocedocard, ascal and a statine. Signs of rejection had not occurred and he had been using co-trimoxazol prophylaxis for six months after transplantation.

At admission, he complained about a severe right-sided headache, fever, shortness of breath, tiredness and night sweats, which existed for at least five weeks. He did not cough but shortness of breath at exertion existed; he only produced a small amount of uncoloured sputum. He did not have noticed differences in urine of micturation.

On physical examination he appeared moderately ill, temperature 38.3°C, blood pressure 120/70 mmHg, pulse rate 108/min. A loud, already known systolic murmur was heard, grade III-IV/VI and also diffuse rhonchi at the right hemithorax. No further abnormalities were found, especially no stigmata of infective endocarditis.

Laboratory results showed leucocytosis (18.1/nl, normal value 4-10/nl) and an elevated C-reactive protein (199 mg/L, normal value < 5 mg/L). Kidney function had mildly deteriorated, serum creatinin 165 umol/l, liver function was without abnormalities. An ECG showed a known right bundle branch block; chest-X-ray showed no signs of pneumonia and sinus radiography was without abnormalities (see Figure 1). Viral swabs remained negative, including on H1N1. Also mastoiditis was ruled out. Although he did not did not reveal signs of sepsis of urinary origin, he was started on ciprofloxacin and cefuroxim.

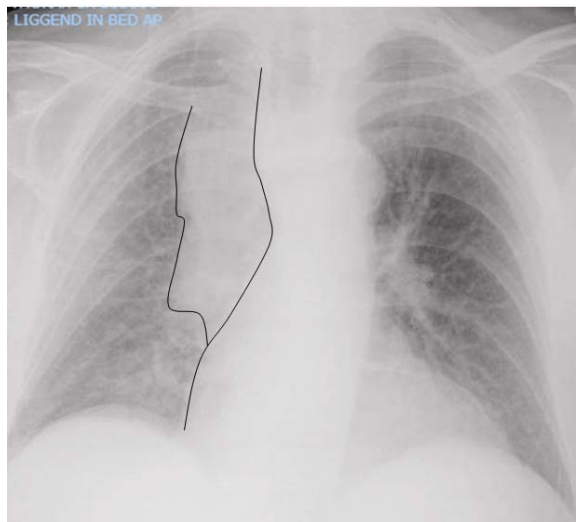


Figure 1. Thoracic X-ray: enlargement mediastinum.

Within 36 hours, both blood- and urine cultures were found positive with *Enterobacter* species. Because of persisting periods of fever, more blood cultures were drawn and incubated in a BacT alert system (Biomérieux, France). After 4 days of incubation the blood cultures became positive with branched Gram-positive rods. Because of the Gram stain and the aspect on the blood agar, this micro-organism was suspected to be a *Nocardia* species. For identification at the genus species level a PCR of the HSP 65 was used ^[1]. The gen product was thereafter sequenced as described by Rodriques-Nava ^[2]. The isolate appeared to be a *Nocardia nova*. Susceptibility testing was performed by E-test (The E-test, AB Biodisk, Solna, Sweden). The micro-organism was susceptible for co-trimoxazole (MIC 0.075 mg/L), meropenem (MIC 0.0032 mg/L), clarithromycin (MIC 0.032 mg/L), ceftriaxone (MIC 0.5 mg/L), linezolid (MIC 0.075 mg/L), and amikacin (MIC 0.125 mg/L) and resistant to moxifloxacin (MIC 2 mg/L), amoxicillin/ clavulanic acid (MIC > 256 mg/L), and minocycline (MIC 4 mg/L).

Immunosuppression was reduced, mycophenolate mofetil was discontinued and antibiotic therapy was switched to meropenem 500 mg 3 times daily. Lumbar puncture showed no signs compatible with meningitis (white blood count $1 \times 10^6/L$, protein 0.26 g/L, glucose 4.4 mmol/L). CT cerebrum and culture of cerebral spinal fluid were negative. His headache, of which he had been complaining for 4 weeks, disappeared with the antimicrobial regimen.

One week after change in antibiotic regime, the patient suddenly became hypotensive with persisting tachycardia, complaining about dyspnoea and chest pain. ECG showed no signs of myocardial ischemia or infarction. A transoesophageal echocardiogram was performed, showing no signs of endocarditis, nor valve-destruction or pericardial fluid. CT-thorax was performed mainly to rule out massive pulmonary embolism. This revealed a large intrathoracic mass, with compression of vena cava superior and right atrium, suspicious for malignancy (see Figure 2). However, in view of the positive nocardia cultures, pulmonary abscesses were suspected and a thoracotomy was performed. A large amount of pus was evacuated in which also *Nocardia nova* was detected. Also a culture of sputum revealed *Nocardia*. Intravenous meropenem was continued and combined with orally administered co-trimoxazol. After an initial short period of improvement, his condition again worsened, mainly because of progressive shortness of breath. A second CT-thorax showed a large amount of pleural fluid at the right hemithorax. Diagnostic pleural puncture exhibited a highly viscous exsudative fluid. Because of this viscous nature, a re-thoracotomy had to be performed. *Nocardia* did not grow in fluid-culture. Following this procedure, the patient recovered and he was planned for percutaneous aorta valve-replacement as soon as he would recover the nocardial infection.

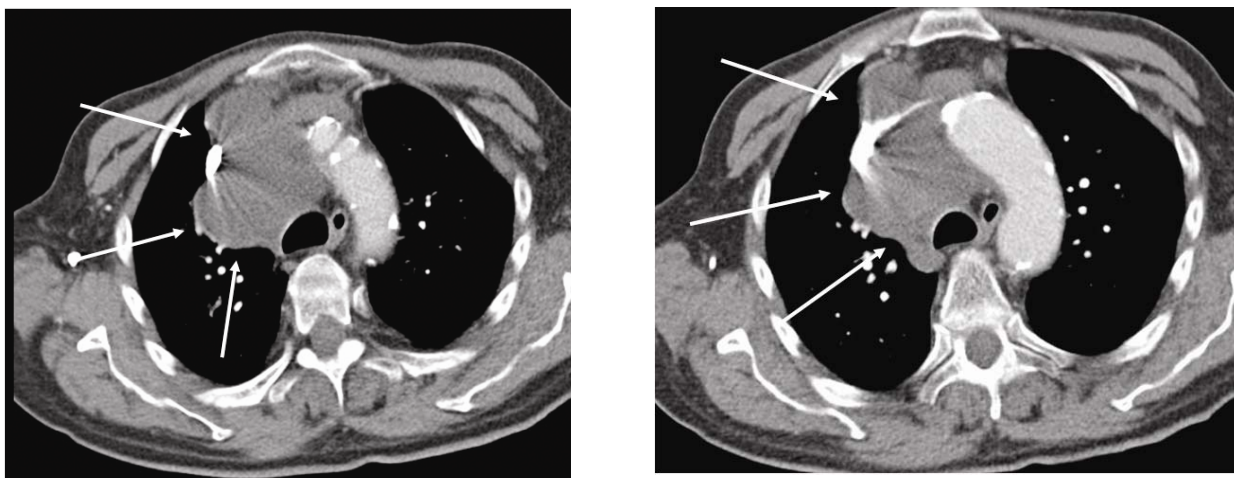


Figure 2. Intrathoracic abscess, compression vena cava information.

Six months after recovery, the patient was admitted again for repeatedly gastro-intestinal bleeding. Neither gastroduodenoscopy nor coloscopy revealed a bleeding location, but a rare aspect of duodenal mucosa was found. Biopsies were performed, which became positive for a *Mycobacterium* species, specified as a *Mycobacterium genavense* (PCR and culture were performed at the Regional Public Health laboratory).

The patient was started on claritromycine and myambutol. Along with diagnosis of this *Mycobacterium* and after starting this treatment, unfortunately his kidney function deteriorated and he developed transplant failure. Because of worsening condition, he was not started on haemodialysis. Two weeks after start treatment for *Mycobacterium* and almost ten months after diagnosis of disseminated Nocardiosis, he died; unfortunately, no postmortal examination was performed.

3 Discussion

This case report describes clinical deterioration and hemodynamic instability because of compression of vena cava superior and right atrium by *Nocardia nova* abscesses. Review of the literature showed only four other cases of vena cava

superior syndrome caused by different species of *Nocardia* [3-6]. Like in our case, in all four patients malignancy was also considered, sometimes delaying diagnosis and treatment. In two cases, drainage was needed to evacuate the effusion, even though the patients were already treated with intravenous antibiotics. One patient, who was allergic to sulphonamide and therefore was treated with streptomycin and erythromycin, died because of ongoing infection and intraspinal dissemination combined with renal failure. This latest was caused by the septic condition, underlying prior condition (systemic lupus) and nephrotoxic medication, one of which being the necessary antibiotics [3].

Our patient died of a co-infection with *M. genavense*, a rare nontuberculous mycobacterium, which is mostly found in patients with inherent or acquired immunodeficiency. Recent reports state that these mycobacteria are increasingly being recognized in solid organ transplant recipients, but because of their diversity, therapy is complex and requires a combination of active antimicrobial agents [7, 8]. In our case, the actual determination and antimicrobial susceptibility guided our treatment, but soon after start of the combined antimicrobial agents, the patient developed transplant failure and died shortly after.

Nocardiosis is a localized or disseminated infection caused by aerobic actinomycete-like bacteria particularly in immunocompromised patients. Its first descriptions in 1888 were made by Edmund Nocard who believed it to be a bovine pathogen [9, 10]. In 1893 Eppinger described the first human case as a pseudotuberculous syndrome in pulmonary disease combined with brain abscesses [11]. Initially this species was thought to be rare, but nowadays, it's obvious these bacteria are responsible for a wide spectrum of diseases, especially in patients with abnormal immune systems [9, 12]. Of the nearly 70 species of the genus *Nocardia*, over 50 have been reported as causing human infection [13, 14].

Human-to-human transmission has not been documented [10, 15]. In most cases, infection is acquired by inhalation of fragmented bacterial mycelia, but transcutaneous inoculation occurs as well as inoculation of the eye [9, 10, 13]. Virulence of *Nocardia* spp depends upon this route of administration and inoculums, but also of growth rate and strain [17]. Natural resistance to infection seems to be high, since frequent contact with the organism in the environment probably occurs [17].

In the US, 1000 cases of Nocardiosis annually are reported, 85% of which is pulmonary or systemic [9, 18]. It is estimated that at least 50% of patients with *Nocardia* species infections have underlying immune compromise [9, 10, 18, 19] and only less than 10% of patients has no definable underlying predisposing factor [17]. Incidence rates after solid organ transplantation differs between 0.7%-4.0% and almost primarily described after renal or heart transplantation [16, 20, 21].

The time after transplantation to onset of Nocardiosis ranges from 1 week tot 338 weeks, with an average interval of 30 weeks [11]. Thus, the first year after transplantation carries the greatest risk and is mostly associated with episodes of allograft rejection (treated with high-dose steroids) and chronic viral infections, especially the presence of immunomodulating viruses like cytomegalovirus. The timeframe after a period of acute rejection to *Nocardia* infection averages sixteen weeks [12, 16, 17].

In over 60% of cases, the lungs are the primary site of *Nocardia* infection. Clinical symptoms include cough, night sweats and fever appearing usually with a subacute pneumonia [9, 10, 15]. Chest X-ray may be normal, but can also include bilateral disease and cavitations in which necrosis leads to the formation of abscesses [12, 14, 16]. As a result, multiple radiographic findings have been demonstrated in nocardiosis, including single or multiple nodules, lung masses [with or without cavitations], reticulonodular infiltrates, interstitial infiltrates, lobar consolidation, subpleural plaques, and pleural effusions. Therefore, nocardiosis has frequently been misdiagnosed initially as tuberculosis [since upper lobe involvement is also common and *Nocardia* spp are weakly acid-fast], invasive fungal disease, and malignancy [20].

Concomitant pleural effusion occurs in 10%-30% of cases and bronchopleural fistulae may develop spontaneously [9]. Initial pulmonary lesions may lead to haematogenous dissemination [12, 18]. Fever, anorexia, weight loss and malaise are common and remission as well as exacerbations are frequent over periods of several weeks [9, 10]. In case of cerebral involvement, headache, lethargy or altered state of consciousness has been reported. Seizures or focal neurological

abnormalities may indicate focal brain infection^[20]. Occasional patients present with subacute or chronic meningitis and during further evaluation brain abscesses are usually found. The combination of headache and unexplained fever in immunosuppressed patients should therefore raise suspicion and necessitate a complete and urgent neurological evaluation by CT of the head and lumbar puncture^[20].

We could not diagnose *Nocardia* in cerebral spinal fluid nor find abnormalities at CT cerebrum in our patient. However, it is known from literature that CNS involvement may occur with gradual or sudden onset of headache and because the headache disappeared as soon as we started the treatment for *Nocardia*, we could not rule out brain involvement.

Although dissemination is presumed to be via haematogenous spread, capture of *Nocardia* in blood cultures is unusual^[9, 16]; routine cultures usually remain negative. Co-infection with more resilient micro-organisms [which frequently exists] or intermittent and infrequent bacteraemia could possibly explain this phenomenon^[20]. Furthermore, *Nocardia* spp is a relatively slow-growing organism which prefers enriched media^[16]. Even on this specific media, culture usually may require 4-21 days to develop characteristic appearance^[9, 11]. Thus, to optimize recognition, the microbiology laboratory should be notified when *Nocardia* is suspected^[9, 10, 15].

Nocardia spp is best examined in cultures of sputum, bronchoalveolar lavage fluid or pus samples from abscess or wound drainages^[9, 10, 16, 18]. Especially in refractory cases, susceptibility testing should be considered, because *Nocardia* species can vary in their antimicrobial susceptibility patterns^[21].

The standard therapy of Nocardiosis consists of prolonged administrations of trimethoprim - sulfamethoxazole (co-trimoxazole). Co-trimoxazole is available in intravenous and in oral form and has excellent pharmacokinetic properties including crossing the blood - barrier barrier^[9, 10, 15]. The in vitro susceptibility testing of *Nocardia* spp has a good correlation with the reducing of colony counts of experimental models^[22]. Despite the use of in vitro sensitivity data to guide therapy, failures occur, often secondary to poor immune status of the host or resistance to several antimicrobial agents^[9].

Alternatives to the standard regimen includes carbapenems, ampicilline, minocycline^[9, 10, 12]. For some *Nocardia* species, third generation cephalosporin may be used, but *N. farcinica* one the most frequent isolated species is relatively resistance to these antimicrobial agents. Linezolid is promising in the treatment of *Nocardia* infections, but because of toxic side effects this drug is not recommended for long-term therapy.

According to the majority of reports, also in case of disseminated infections a combination of two different drugs are advocated. In an immunocompromised mice-model, imipenem and amikacine appeared to be the most bactericidal regime^[22], but due to its poor CNS penetration, this combination does not provide optimal therapy. Another carbapenem, i.e. meropenem, is often used instead of imipenem because of the minor chance of convulsions. As in our patient, abscesses or purulent effusions should be treated with aspiration and/ or drainage if possible, especially if these are large and does not respond sufficiently to antibiotics^[9, 16, 19].

Nocardia-infections tend to relapse so long courses of antimicrobial therapy are often needed^[20]. Due to the lack of comparative clinical studies, the optimal therapy for Nocardiosis is not known especially since time to relapse ranges from one month to several years after previous infection^[10, 15, 19]. Treatment duration of at least six months is recommended for immunocompromised patients and therapy in CNS nocardiosis or extensive infection should be at least continue for 12 months^[9, 12, 15].

Worldwide, co-trimoxazol prophylaxis for pneumocystis jirovecii is recommended in solid organ transplantations at least for six months after transplantation^[17]. This prophylactic regime also gives protection against other opportunistic infections such as toxoplasmosis and listeriosis. However, this low dose prophylaxis is not a guarantee for absolute protection against *Nocardia* infection despite favourable susceptibility results^[9].

Due to the long lasting course of infection and the risk of dissemination or formation of abscesses, mortality of pulmonary or systemic nocardiosis is estimated at 15%-40%, but involvement of CNS increases the mortality^[10]. Overall mortality rate is 44%-85%, depending on the underlying immune status of the host^[9, 14, 19]. It is estimated that 10% of the infectious death after organ transplant is due to Nocardiosis^[9].

4 Conclusion

Nocardia spp is an opportunistic pathogen, causing a spectrum of diseases ranging from non-specific subacute pneumonia to formation of pulmonary abscesses. As the presenting symptoms are non-specific, there is usually a delay in diagnosis. It is important not to misinterpret any pulmonary lesion and to suspect opportunistic diseases like Nocardiosis, especially in immunosuppressed patients who develop pulmonary symptoms^[14].

Even for seemingly minor findings CT or MRI of lungs, abdomen or brain should be considered, especially when disseminated disease is suspected^[9, 12, 18].

Therapy of choice is co-trimoxazol, although animal studies have shown that imipenem combined with amikacyn may be the best opportunity. Duration of therapy should be long, especially in disseminated disease and exacerbations. Complications such as empyema, mediastinitis, pericarditis, and superior vena cava syndrome can occur following contiguous spread of nocardial infection from a lung, pleural, or cutaneous focus^[3, 4, 23].

Mortality rates are high, despite long courses of treatment. Our clinical case describes a patient who became haemodynamic unstable because of compression of vena cava superior and right atrium and needed an urgent operation to be stabilized. By our knowledge, there are only a few cases described in literature with an infection to this extent.

References

- [1] Telenti A, Marchesi F, Balz M, Bally F, Böttger EC, Bodmer T. Rapid identification of mycobacteria to the species level by polymerase chain reaction and restriction enzyme analysis. *J Clin Microbiol.* 1993 Feb; 31(2): 175-8.
- [2] Rodríguez-Nava V, Couble A, Devulder G, Flandrois JP, Boiron P, Laurent F. Use of PCR-restriction enzyme pattern analysis and sequencing database for hsp65 gene-based identification of *Nocardia* species. *J Clin Microbiol.* 2006 Feb; 44(2): 536-46. <http://dx.doi.org/10.1128/JCM.44.2.536-546.2006>
- [3] Chapman JR, Walesby RK. *Nocardia Asteroides* causing vena caval obstruction. *British Journal of Diseases of the Chest.* 1981; 75: 99-102. [http://dx.doi.org/10.1016/S0007-0971\(81\)80015-0](http://dx.doi.org/10.1016/S0007-0971(81)80015-0)
- [4] Abdelkafi S, Dubail D, Bosschaerts T, Brunet A, van Camp G et al. Superior vena cava syndrome associated with *Nocardia farcinica* infection. *Thorax.* 1997; 52: 492-493. <http://dx.doi.org/10.1136/thx.52.5.492>
- [5] Pitchenik AE, Zaunbrecher F. Superior vena cava syndrome caused by *Nocardia asteroides*. *American Rev. Respiratory Disease.* 1978; 117 (4): 795-798.
- [6] Rankin RS, Westcott JL. Superior vena cava syndrome caused by *Nocardia mediastinitis*. *American Rev. Respiratory Disease.* 1973; 108 (2): 361-363.
- [7] Razonable RR. Nontuberculous mycobacterial infections after transplantation: a diversity of pathogens and clinical syndromes. *Transplant Infectious Disease.* 2009; 11: 191-194. <http://dx.doi.org/10.1111/j.1399-3062.2009.00392.x>
- [8] Doggett J.S, Strasfeld L. Disseminated Mycobacterium Genavense with pulmonary nodules in a kidney transplant recipient: case report and review of the literature. *Transplant Infectious Disease.* 2011; 13: 38-43. <http://dx.doi.org/10.1111/j.1399-3062.2010.00545.x>
- [9] Lederman ER, Crum NF. A Case series and focused review of Nocardiosis. *Clinical and Microbiologic Aspects. Medicine.* 2004; 83(5): 300-313. <http://dx.doi.org/10.1097/01.md.0000141100.30871.39>
- [10] Martinez R, Reyes S, Menedez R. Pulmonary nocardiosis: risk factors, clinical features, diagnosis and prognosis. *Current Opinion in Pulmonary Medicine.* 2008; 14: 219-227. <http://dx.doi.org/10.1097/MCP.0b013e3282f85dd3>
- [11] Wilson JP, Turner HR, Kirchner KA, Chapman SW. Nocardial infections in renal transplant recipients. *Medicine.* 1989; 68: 38-57. <http://dx.doi.org/10.1097/00005792-198901000-00003>

- [12] Tolkoff-Rubin NE, Rubin RH. Opportunistic Fungal and Bacterial Infection in the renal transplant recipient. *Journal of the American Society of Nephrology*. 1992; 2(s3): 264-269.
- [13] Conville PS, Wiitesby FG. *Nocardia Rhodococcus, Gordonia, Actinomadura, Streptomyces and other Aerobic Actinomycetes In Manual of Clinical Microbiology* 9 th ed. Washington DC: ASM press; 2007. 515- 542.
- [14] Farina C, Boiron P, Ferrari I, Provost F, Goglio A. Report of Human Nocardiosis in Italy between 1993-1997. *European Journal of Epidemiology*. 2001; 17: 1019-1022. <http://dx.doi.org/10.1023/A:1020010826300>
- [15] Mari B, Monton C, Mariscal D, Lujan M, Sala M et al. Pulmonary Nocardiosis: clinical experience in ten cases. *Respiration*. 2001; 68: 382-388. <http://dx.doi.org/10.1159/000050531>
- [16] Patel R, Paya CV. Infections in solid-organ transplant recipients. *Clinical Microbiology Reviews*. 1997; 10: 86-124
- [17] Peleg AY, Husian S, Qureshi ZA, Silviera FP, Sarumi M et al. Risk Factors, Clinical characteristics and outcome of nocardia infection in organ transplant recipients: a matched case-control study. *Clinical Infectious Diseases*. 2007; 44: 1307-1314. <http://dx.doi.org/10.1086/514340>
- [18] Simpson GL, Stinson EB, Egger MJ, Remington JS. Nocardial infections in the immunocompromised host: a detailed study in a defined population. *Reviews of Infectious diseases*. 1981; 3(3): 492-507. <http://dx.doi.org/10.1093/clinids/3.3.492>
- [19] King CT, Chapman SW, Butkus DE. Recurrent Nocardiosis in a renal transplant recipient. *Southern Medical Journal*. 1993; 86(2): 225-228. <http://dx.doi.org/10.1097/00007611-199302000-00018>
- [20] Fishman JA, Rubin RH. Infection in organ-transplant recipients. *The New England Journal Medicine*. 1998; 338 (24): 1741-1751. <http://dx.doi.org/10.1056/NEJM199806113382407>
- [21] Saubolle MA, Sussland D. Nocardiosis: Review of Clinical and Laboratory Experience. *Journal of Clinical Microbiology*. 2003; 41 (10): 4497-4501. <http://dx.doi.org/10.1128/JCM.41.10.4497-4501.2003>
- [22] Gompert ME, Berkowitz LB, Aulicino TM, Bouchet L: Therapy of pulmonary Nocardiosis in Immunocompromised Mice. *Antimicrobial Agents Chemotherapy*. 1990; 34: 1766-1768. <http://dx.doi.org/10.1128/AAC.34.9.1766>
- [23] Feigin DS. Nocardiosis of the Lung: Chest Radiographic Findings in 21 Cases. *Radiology*. 1986; 159: 9-14.