

CASE REPORT

“Buddenbrook syndrome” - Toothache and its serious consequences

Ulrike Maria Müller, Madlen Uhlemann, Sabrina Wolff, Marcus Sandri, Gerhard C. Schuler

Department of Internal Medicine / Cardiology, University Leipzig, Germany.

Correspondence: Ulrike Maria Müller. Address: Department of Internal Medicine / Cardiology, University Leipzig, Germany. Email: ulrike.mueller@herzzentrum-leipzig.de

Received: October 17, 2014

Accepted: November 13, 2014

Online Published: January 14, 2015

DOI: 10.5430/crim.v2n2p10

URL: <http://dx.doi.org/10.5430/crim.v2n2p10>

Abstract

Background: Atypical symptoms of acute coronary syndrome are associated with increased mortality due to missed diagnosis and treatment delay. Misleading mandible pain as odontogenic instead of cardiac origin may be termed as Buddenbrook syndrome. The name is derived from Thomas Mann's (1875-1955) novel Buddenbrooks, where one of the main characters, Consul Thomas Buddenbrook, further complained of jaw pain after teeth extraction and died shortly after due to myocardial infarction.

Case Description: We present a patient with mandible pain, who collapsed at his dentist with the need of prolonged resuscitation due to incessant ventricular fibrillation (VF) caused by acute myocardial infarction. Despite uncertain neurologic prognosis after more than 60 minutes of external cardiopulmonary resuscitation (CPR) and persistent cardiogenic shock 24 hours later we decided to implant an ECMO as the last therapeutic option. The patient improved and could be discharged four weeks later in good neuro- and cardiologic condition.

Clinical Implications: The primary cardiac cause of mandible or toothache may remain undiscovered if teeth also show a correlate for symptoms and may have adverse outcome. Dentists should think of cardiac origin especially in recurrent symptoms or patients with cardiovascular risk factors.

Keywords

Cardiogenic shock, Myocardial infarction, Mandible pain

1 Introduction

Coronary heart disease has multiple faces. To differentiate thoracic pain several questions may help: In which situation does the pain occur, where is it localized, what nature has the pain, how long is the duration, does it react on nitroglycerine, and does it change to breathing or position?

In some patients toothache is the only symptom for unstable angina and impending myocardial infarction (MI). Atypical symptoms of acute coronary syndrome are associated with increased mortality. Acute MI may result in ventricular fibrillation, resuscitation, cardiogenic shock and multi organ failure. If duration of resuscitation is prolonged, decision to life-sustaining measures may be difficult due to uncertain intracerebral situation and higher bleeding risk under life-support machine (e.g. extra corporal membrane oxygenation, ECMO).

In our case report we present a patient who went several times to his dentist due to toothache, collapsed down in the waiting room, was prolonged, but successfully resuscitated, received thrombolysis and percutaneous coronary intervention (PCI), needed ECMO, and finally survived with good clinical and neurological outcome.

2 Case report

A 56-year-old obese man (body mass index 35 kg/m²), who has had in the past often trouble with his teeth, complained of recurrent mandible pain and went twice to his dentist. The dentist removed a dental bridge and prescribed analgetics.

Three days later the mandible pain recurred with much more intensity, so that the patient went again to his dentist, where he collapsed in the waiting room. CPR was immediately started. First rhythm documented was asystole. After chest compression ventricular fibrillation (VF) occurred and was treated with several defibrillations and amiodarone intravenously. The patient was transferred under resuscitation to the next hospital, where a thrombolysis with 10000 IE tenecteplase was performed due to ST-elevation myocardial infarction (STEMI). An electrocardiogram (ECG) showed ST-elevation in inferior and anterior leads (Figure 1a and 1d). Furthermore intermittent complete atrioventricular block occurred. Spontaneous circulation could be reestablished after 45 minutes CPR. Rhythm remained unstable and further defibrillations on VF were necessary. The patient was intubated, received external cooling and was transferred to a hospital with PCI facility. Arterial blood gas analysis at admission is shown in Table 1a.

Coronary angiography revealed a single vessel disease with thrombotic occlusion of the proximal right coronary artery (RCA, Figure 1b). After thrombectomy, a drug eluting stent was implanted (Figure 1c). Therapeutic hypothermia was continued for 24 h using an internal cooling system. Transthoracic echocardiography revealed a reduced left ventricular function of 45% with posterior hypokinesia and right ventricular (RV) dilatation with reduced RV contractile function. Recurrent VF led to further defibrillations and further episodes of chest compressions of overall more than 15 min. Due to persistent cardiogenic shock despite volume repletion and increasing catecholamine therapy, and multi organ failure we decided to implant a peripheral veno-arterial ECMO about 16 hours after PCI. Laboratory values are given in Table 1b. Patient received antibiotics due to an aspiration pneumonia. Five days later, hemodynamic situation had stabilized and ECMO was explanted. After finishing receiving sedatives patient recovered from coma with completely normal neurologic functions. Patient was discharged from hospital four weeks after admission. In a follow-up 8 weeks after his infarction nt-proBNP was still elevated (999 ng/l, normal < 100 ng/l), but patient was able to perform 100 Watt at ergometry stress test without symptoms of dyspnea or angina. He especially denied recurrence of mandible pain.

Table 1. Blood gas analysis and laboratory values

(a) Arterial blood gas analysis			(b) Laboratory values		
Pressure controlled ventilation			Parameter	Value	Normal value
	Admission	24 hours			
pH	7.075	7.38	Creatinine (μmol/l)	435	<106
pCO ₂ (mmHg)	71	34	GFR (ml/min/1.73 m ²)	13.1	90-120
pO ₂ (mmHg)	82	98	CK max (mol/l*s)	199	<3.17
sO ₂ (%)	90	98	CK MB (μmol/l*s)	2.43	<0.17
Horowitz index (mmHg)	93	122	Troponin T (ng/l)	>10,000	<14
Base excess (mmol/l)	-8.9	-4.3	GOT (μmol/l*s)	2.12	0.17-0.85
HCO ₃ (mmol/l)	15	14.5	Leucocytes (Gpt/l)	13	4.4-11.30
Glucose (mmol/l)	15.7	8.5	Platelets (Gpt/l)	70	150-400
Hemoglobin (mmol/l)	9.1	6.9			
Lactate (mmol/l)	6.2	4.8			

Note. a) Arterial blood gas analysis after admission to tertiary care hospital two hours after begin of resuscitation and just before ECMO implantation. b) Multi organ failure documented in several laboratory values within the first 24 hours of admission.

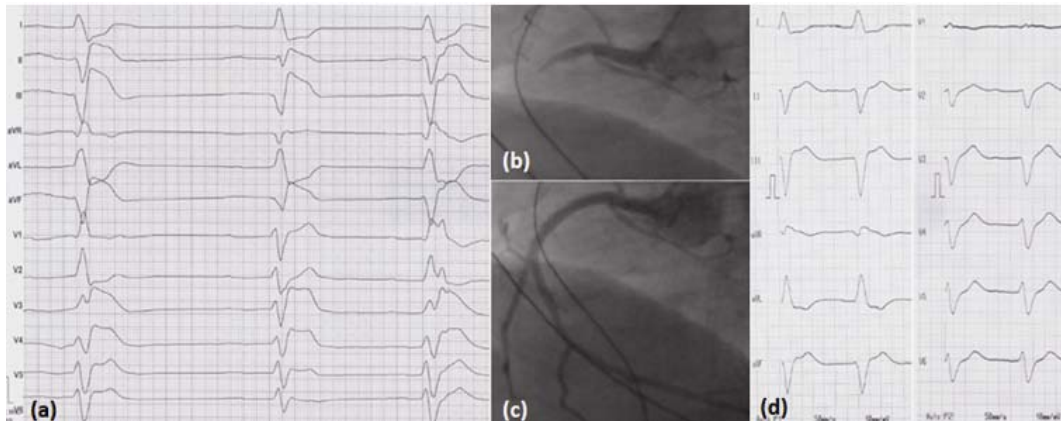


Figure 1. a) ECG after successful resuscitation. ST segment elevation in II, III, aVF and reciprocal ST segment depression and T inversion in I, aVL, V2. Anterior leads (V3-V5) show ST segment elevation that mimics an anterior infarction, but is with a positive axis the sign of a right heart infarction. b) Coronary angiography of the right coronary artery: thrombotic occlusion despite thrombolysis performed two hours before. c) RCA after stent implantation. d) ECG just before stent implantation, 90 minutes from the first performed ECG (a). Q and ST segment elevation in II, III, aVF. Reciprocal ST segment depression and T inversion in I, aVL. ST elevation in V3 and V4 as in (a) are not furthermore present. In inferior infarction a right heart ECG with leads V3r and V4r should be documented as early as possible.

3 Discussion

Atypical symptoms of acute coronary syndrome are associated with increased mortality due to missed diagnosis and treatment delay (1). About 40% of patients complain of craniofacial pain with or without concomitant typical angina pectoris, but in about 6% craniofacial pain is the only symptom of cardiovascular disease (2). Singular mandible pain in a patient who often has problems with his teeth (as in presented case), may be partly differentiated as cardiac origin in anamnesis: it occurs in lower jaw (mandible) and, in contrast to pain of odontogenic origin, it usually crosses the midline (3). Misleading mandible pain as odontogenic instead of cardiac origin may be termed as Buddenbrook syndrome. The name is derived from German poet Thomas Mann's (1875-1955) famous novel Buddenbrooks, where one of the main characters, Consul Thomas Buddenbrook, further complained of mandible pain after teeth extraction and died shortly afterwards due to myocardial infarction. The primary cardiac cause of mandible or toothache may remain undiscovered if teeth also show a correlation with symptoms.

RV infarction may occur in isolation or, far more frequently in 30 to 50%, in connection with inferior wall STEMI (4), especially in case of proximal occlusion of RCA. Most patients have ST-segment elevation ≥ 0.1 mV in V1, V3R and V4R. In our patient V3 and V4 were elevated, that can be confused with elevation caused by anteroseptal infarction. Elevated ST segments are oriented anteriorly in both cases. However, the ST segments are oriented to the right in RV infarction (e.g. +120 degrees), whereas they are oriented to the left in anteroseptal infarction (e.g. -30 degrees, (5)).

It is necessary to diagnose right heart involvement because there are different therapeutic strategies. In infarction with mainly impairment of left heart function, danger of volume overload with consecutive lung edema has to be in mind. Diuretics and nitrates are usually administered. In right heart infarction high preload is necessary with volume application. However, acute reduction of RV contractibility may cause RV volume overload and pressure elevation. In consequence, this causes an impairment of left ventricular filling, results in a relevant reduction of cardiac index and ends in a combined biventricular failure (6). Then, as in our case, an ECMO support seems to be the best life-saving possibility. Favorable

outcome of our patient justified retrospectively the decision in consideration of prolonged resuscitation, despite of multi organ failure, obesity, activated coagulation status, but also young age.

4 Conclusion

Buddenbrook angina should not be missed as a differential diagnosis in patients with mandible pain. ECMO is a reasonable therapeutic strategy even in multiple organ failure in persistent cardiogenic shock, and should also be discussed in uncertain neurologic status after resuscitation. Intensive care medicine proves to may have success in apparently hopeless situations.

Reference

- [1] Pope JH, Aufderheide TP, Ruthazer R et al. Missed diagnoses of acute cardiac ischemia in the emergency department. *N Engl J Med.* 2000; 342(16): 1163-1170. PMID:10770981 <http://dx.doi.org/10.1056/NEJM200004203421603>
- [2] Kreiner M, Okeson JP, Michelis V, Lujambio M, Isberg A. Craniofacial pain as the sole symptom of cardiac ischemia: a prospective multicenter study. *J Am Dent Assoc.* 2007; 138(1): 74-79. PMID:17197405 <http://dx.doi.org/10.14219/jada.archive.2007.0024>
- [3] Falace DA, Reid K, Rayens MK. The influence of deep (odontogenic) pain intensity, quality, and duration on the incidence and characteristics of referred orofacial pain. *J Orofac Pain.* 1996; 10(3): 232-239. PMID:9161228
- [4] Steg PG, James SK, Atar D et al. ESC Guidelines for the management of acute myocardial infarction in patients presenting with ST-segment elevation. *Eur Heart J.* 2012; 33(20): 2569-2619. PMID:22922416 <http://dx.doi.org/10.1093/eurheartj/ehs215>
- [5] Antman EM, Morrow DA. Right ventricular infarction. In: Bonow RO, Mann DL, Zipes DP, Libby P, editors. *Braunwald's Heart Disease - A Textbook of cardiovascular medicine.* 9 th ed. Philadelphia: Elsevier; 2012:1146-1147.
- [6] Goldstein JA. Pathophysiology and management of right heart ischemia. *J Am Coll Cardiol.* 2002; 40(5): 841-853. [http://dx.doi.org/10.1016/S0735-1097\(02\)02048-X](http://dx.doi.org/10.1016/S0735-1097(02)02048-X)