

CASE REPORT

Serratia marcescens lung abscess with review of a Japanese national inpatient database

Kazuko Miyakawa¹, Yasushi Goto¹, Mitushiro Sunohara¹, Hideo Yasunaga², Takahide Nagase¹

1. Department of Respiratory Medicine, Graduate School of Medicine, The University of Tokyo, Tokyo, Japan.
2. Department of Health Economics and Epidemiology Research, The University of Tokyo, Tokyo, Japan.

Correspondence: Yasushi Goto. Address: Department of Respiratory Medicine, The University of Tokyo Hospital 113-8655 7-3-1, Hongo, Bunkyo-ku, Tokyo, Japan. Email: ygoto-tky@umin.net

Received: December 10, 2014

Accepted: March 15, 2015

Online Published: March 18, 2015

DOI: 10.5430/crim.v2n2p40

URL: <http://dx.doi.org/10.5430/crim.v2n2p40>

Abstract

Radiographic examination of an 80-year-old male patient with diabetes mellitus taking prednisolone (30 mg per day) for IgG₄-related disease (cholangitis and pancreatitis) indicated consolidation within the lung cavity. Repeated bronchoscopies allowed us to diagnose a lung abscess caused by *Serratia marcescens*. Treatment with cephem antibiotics was effective, and was continued for 3 months. There was no sign of relapse. *Serratia marcescens* lung abscess is relatively rare, as we found only 14 cases pneumonia of *Serratia* species in 1.5 million cases of hospitalized patients in national administrative database of Japan.

Keywords

Bronchoscopy, Immunocompromised, Lung abscess, National database, *Serratia marcescens*

1 Introduction

Serratia marcescens has long been regarded as a harmless nonpathogenic organism. Recently, however, its importance as an etiological agent of nosocomial infections and opportunistic infections has been recognized. *S. marcescens* is an established human pathogen associated with urinary tract infections, pneumonia, bloodstream infections, and surgical site infections. Here we report a case of *S. marcescens* lung abscess. As this condition is relatively rare, we searched for lung infection due to *Serratia marcescens* in the national database.

2 Case report

An 80-year-old male patient was admitted to our hospital for glycemic control. He had been diagnosed with IgG₄-related disease two months prior and was started on prednisolone (30 mg/day). One-and-a-half months prior, the patient was admitted to the intensive care unit due to non-ketotic hyperosmolar coma with hyperglycemic state.

Chest radiography showed a consolidation on the patient's right upper lobe (see Figure 1). Computed tomography scan revealed a consolidation and a large cavity with thick irregular margin, which was not seen 3 months previously (see Figure 2a and 2b). He had no clinical symptoms. His laboratory tests revealed slight elevation in white blood cell

(9,500 / μ L). All tests for (1-3) β -D glucan, serum *Aspergillus* antigen, serum cryptococcus antigen, c-ANCA, and tumor markers were negative.

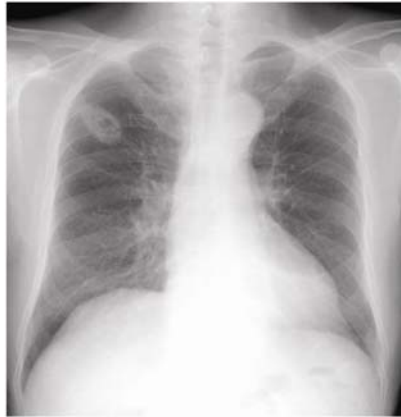

Figure 1. Chest radiograph taken on admission. Consolidation and a cavity are evident in the right upper area.

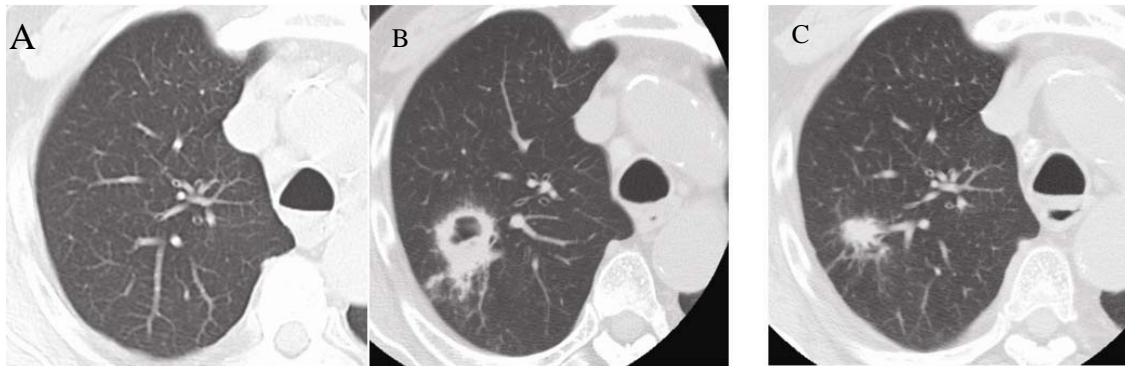


Figure 2. Changes in computed tomography scan data over time. A) Three months before admission; B) on admission (a large cavity with a thick irregular margin, located in the right upper lobe, is evident), C) 3 months after commencement of antibiotic therapy (the cavity has disappeared and only residual scarring is evident).

Serratia marcescens was identified by culture of the patient's sputum. Bronchoscopy was performed to rule out other diagnoses such as mycobacterium infection, lung abscess, fungal infection, granulomatosis with polyangitis, tumors, and sarcoidosis. Biopsy revealed necrotic tissue but no malignant cells, granulomas, nor vasculitis. Microbiological cultures of the bronchial lavage fluid revealed only *Serratia marcescens*. As lung abscesses caused by *S. marcescens* are uncommon, we performed repeated bronchoscopies, guided by endobronchial ultrasonography, to explore the lung cavity directly. Identical results were obtained.

The patient was treated with intravenous ceftriaxone and oral metronidazole for 9 days. Antibiotics were subsequently changed to oral cefcapene pivoxil and continued for 3 months. The radiographic findings showed improvement and the large cavity had disappeared (see Figure 2c). Although *Serratia marcescens* is still cultured from the septum, no relapse has been detected after discontinuing antibiotic treatment.

3 Methods

Japan maintains a national administrative claim database termed the Diagnosis Procedure Combination (DPC). This database details co-existing illnesses evident on hospital admission, and procedures undergone and medications administered, while hospitalized. Database details have been described elsewhere^[1, 2].

We used national database collected by the DPC study group between July and December of all of the years 2007-2010, and full-year data from 2011-2013. DPC database do not distinguish between pneumonia and lung abscess. Therefore, we extracted information on patients diagnosed lung infection, which is assigned as pneumonia on hospital admission. We focused on patients with diagnoses of “Pneumonia due to *Serratia marcescens*”, which may include *Serratia marcescens* lung abscess. We examined patient backgrounds and coexisting illnesses.

4 Results

We found 14 cases diagnosed with “Pneumonia due to *Serratia marcescens*”, of whom 10 (71%) were male. All patients but one were older than 60 years; one 34-year-old patient also had cerebral palsy. Seven of twelve patients (58%) whose height and weight were recorded were underweight, with body mass indices less than 18.5 kg/m². Seven patients (50%) had coexisting illnesses linked to aspiration, such as recent cerebral infarction associated with gastrostomy, or paralysis of the recurrent nerve caused by laryngeal carcinoma.

5 Discussion

Lung abscess due to microbial pathogens generally arise in patients with some complications. Anaerobes and other bacteria such as *S. aureus*, *K. pneumonia*, and gram-negative bacilli, are main microbiological causes. Various risk factors could lead to lung abscess. The patient reported in this study had poorly controlled diabetes mellitus, and was in a state of immunocompromise due to corticosteroid taken for IgG4 disease.

Serratia marcescens is a gram-negative bacillus of the Enterobacteriaceae group of bacteria. The reported incidence of *Serratia* infections is relatively low (estimated to be 10.8 per 100,000 people annually) [3]. Most cases are uncommon causes of hospital-acquired infections. It is even more rare for patients to have lung abscess due to *Serratia marcescens*. Reports indicate that 1 of 74 patients with *Serratia marcescens* have lung abscesses [4], and only two detailed cases are reported in PubMed. One patient was a 70-year-old male with thrombophlebitis and chronic pyelonephritis [5], and another was a 5-year-old boy with autoimmune neutropenia [6]. Since this condition is rare, and *Serratia marcescens* is one of the oral normal inhabitants and may not be the disease-producing bacteria, we repeatedly examined sputum and lavage fluid with bronchoscopy, and found that *Serratia marcescens* was the definitive pathogen. The patient was admitted to the intensive care unit for 1 day, therefore had hospital-acquired *Serratia marcescens* infection. Treatment with cephem antibiotics was effective.

Since *Serratia marcescens* lung abscess is rare, we looked for the national administrative database to find the incidence and patients' characteristics of this condition. Unfortunately, we could not differentiate pneumonia from lung abscesses caused by *Serratia* because the two conditions were not separately recorded in the national administrative database. Therefore we revealed certain clinical characteristics of *Serratia* pneumonia patients; these were male gender, advanced age, emaciation, and the presence of coexisting illnesses associated with dysphagia. Our patient was not emaciated, but was experiencing dramatic weight loss, probably caused by diabetes mellitus. We did not record dysphagia in our patient.

When *Serratia marcescens* is identified in immunocompetent patient, we should first be suspicious of contamination or colonization. When diagnosing a patient to have *Serratia marcescens* as disease-producing bacteria, we need to confirm several issues. Firstly, clinical condition must be in accordance with *Serratia marcescens* infection. *Serratia marcescens* tend to colonize in the respiratory and urinary tracts, and less frequently in the gastrointestinal tract. Secondly, no other bacterium, which is more likely to be disease producing, is detected. Thirdly, diagnosis will be more clarified when *Serratia marcescens* is repeatedly detected from the infection site. Our patient had fulfilled all these clinical conditions.

Lung abscess with *Serratia marcescens* is a rare disease. However, appropriate laboratory testing can provide an accurate diagnosis. In the present article, we have also identified several possible risk factors for *Serratia marcescens* infections;

these include male gender, advanced age, emaciation, and the presence of coexisting illnesses associated with dysphagia. Reported patients had implemented with some of the risk factors. The presence of a lung abscess caused by *Serratia marcescens* should be considered in patients exhibiting risk factors.

References

- [1] Hamada T, Yasunaga H, Nakai Y, et al. Impact of hospital volume on outcomes in acute pancreatitis: a study using a nationwide administrative database. *J Gastroenterol*. 2014 Jan; 49(1): 148-55. <http://dx.doi.org/10.1007/s00535-013-0888-9>
- [2] Sato M, Tateishi R, Yasunaga H, et al. Acute liver disease in Japan: a nationwide analysis of the Japanese Diagnosis Procedure Combination database. *J Gastroenterol*. 2014 Mar; 49(3): 547-54.
- [3] Laupland KB, Parkins MD, Gregson DB, et al. Population-based laboratory surveillance for *Serratia* species isolates in a large Canadian health region. *Eur J Clin Microbiol Infect Dis*. 2008 Feb; 27(2): 89-95. <http://dx.doi.org/10.1007/s10096-007-0400-7>
- [4] Balikian JP, Herman PG, Godleski JJ. *Serratia pneumonia*. *Radiology*. 1980 Nov; 137(2): 309-11. <http://dx.doi.org/10.1148/radiology.137.2.7001538>
- [5] Elston HR, Magnuson CW. Lung abscess caused by nonchromogenic *Serratia marcescens*. *Am Rev Respir Dis*. 1965 Oct; 92(4): 624-31. PMID:5319449
- [6] Mizota M, Kawakami K, Ijichi O, et al. *Serratia marcescens* lung abscess in a child with autoimmune neutropenia. *Acta Paediatr Jpn*. 1995 Jun; 37(3): 377-80. PMID:7645393 <http://dx.doi.org/10.1111/j.1442-200X.1995.tb03335.x>