

CASE REPORTS

Catastrophic antiphospholipid syndrome (CAPS) precipitated by cardiac surgery: A case report and review of the literature

Shivani J. Gandhi*¹, Igor Medic², Neil A. Lachant²

¹Department of Internal Medicine, Cooper University Health Care, Camden, USA

²Division of Hematology and Oncology, MD Anderson Cancer Center at Cooper, Camden, USA

Received: July 21, 2016

Accepted: September 18, 2016

Online Published: October 7, 2016

DOI: 10.5430/crim.v3n4p73

URL: <http://dx.doi.org/10.5430/crim.v3n4p73>

ABSTRACT

Background: A devastating complication of antiphospholipid syndrome (APS) is catastrophic antiphospholipid syndrome (CAPS), which is extremely rare, difficult to diagnose, and portends a poor prognosis with high mortality. Intra-abdominal and obstetric surgeries have been regarded as precipitating factors in the development of CAPS in patients with pre-existing APS. We present the unique case of a patient who developed CAPS as an immediate complication after valvular replacement surgery.

Case presentation: A 57-year-old female was admitted for acute decompensated heart failure secondary to mitral valve stenosis. Her past medical history was suspicious for APS, but she was not formally diagnosed or started on anticoagulant therapy. She ultimately underwent mitral valve replacement. One week post-operatively, she developed intractable abdominal pain, progressive renal failure and thrombocytopenia, and behavioral changes over the course of several days. Extensive investigation for infection, thrombotic thrombocytopenic purpura (TTP), heparin-induced thrombocytopenia (HIT) and disseminated intravascular coagulation (DIC) did not explain her rapid clinical deterioration. She did, however, fulfill the criteria for probable CAPS, given that she had rapid involvement of four organ systems and persistent antiphospholipid antibodies. She was started on both plasmapheresis and hemodialysis 12 days postoperatively, and showed significant improvement in her mentation, abdominal pain, thrombocytopenia, and renal function.

Conclusion: This case illustrates the high degree of clinical suspicion and understanding of precipitating factors that are required to make a diagnosis of CAPS; furthermore, it delineates the life-saving impact of effective treatment. The correlation of CAPS and surgery has been observed in several reports. However, the current literature posits that CAPS is seldom a complication of cardiac surgery, and more frequently an immediate complication after abdominal or obstetric surgeries. For this reason, this case is novel in that it represents one of the few cases in which CAPS was triggered by cardiac surgery involving cardiopulmonary bypass (CPB).

Key Words: Catastrophic antiphospholipid syndrome, Antiphospholipid syndrome, Catastrophic antiphospholipid syndrome

1. INTRODUCTION

Antiphospholipid syndrome (APS) is an autoimmune condition manifested by venous/arterial thromboses, recurrent

pregnancy loss and persistently positive antiphospholipid antibodies.^[1,2] These auto-antibodies include anticardiolipin antibodies, anti-beta-2-glycoprotein-1 antibodies, and the

*Correspondence: Shivani J. Gandhi, DO; Email: Gandhi-shivani@cooperhealth.edu; Address: Cooper University Hospital, 401 Haddon Avenue, E&R Building, Third Floor, Camden, NJ 08103, USA.

lupus anticoagulant. A serious but less common variation of APS is catastrophic antiphospholipid syndrome (CAPS). Patients with CAPS represent approximately 1% of all patients with APS, but the mortality of this condition has been shown to be approximately 50% despite optimal therapy.^[2] As opposed to APS, which often involves large vessel thrombosis, the clinical manifestations of CAPS tends to be dominated by occlusion of small vessels and involvement of multiple organs at once.^[2] Catastrophic antiphospholipid syndrome has a tendency to present in an evolving and sometimes vague

manner, necessitating a high degree of clinical suspicion. Although exceedingly rare, many investigations have sought to determine the triggers of CAPS. The major precipitants of this syndrome include trauma, surgery, infection, and inadequate anticoagulation. Furthermore, recent studies have suggested that there is a spectrum of CAPS, comprising of patients that have evidence of unexplained multiple organ dysfunction, and fulfill the criteria for either “definite” or “probable” CAPS (see Table 1).^[1,2]

Table 1. Preliminary classification criteria for catastrophic antiphospholipid syndrom

1. Evidence of involvement of three or more organ systems
2. Development of manifestations simultaneously or with < 1 week
3. Histopathologic evidence of small vessel occlusion
4. Laboratory confirmation of antiphospholipid an
– Positive antibodies on 2 occasions at least 6 weeks apart, if the patient does not have a previous diagnosis of APS
• Definite CAPS = all four criteria
• Probable CAPS
– Criteria 1, 2 and 4 present
– Criteria 1, 3 and 4 present with development of a third event between 1 week – month of presentation of a third event between 1 week – 1 month of presentation, despite anticoagulation
Adapted from: Asherson <i>et al.</i> , 2013

As shown in Table 1, there are several clinical and laboratory criteria that should be met in order to make a diagnosis of catastrophic antiphospholipid syndrome. Furthermore, based

on the number of criteria fulfilled, patients can have definite or probable CAPS.

Table 2. Antiphospholipid antibody studies

Antiphospholipid antibody studies	Initial	Follow-up after 6 weeks	Normal values
Prothrombin time (PT)	10 sec	11.3 sec	9.5-12.2 sec
Activated partial thromboplastin time (aPTT)/Lupus anticoagulant (LAC) screen	69 sec	68.7 sec	26.3-36.0 sec
Thrombin time	17 sec	17 sec	15-19 sec
Hexagonal phase phospholipid neutralization assay	Positive	Positive	Negative
Dilute Russel’s Viper Venom Time (DRVVT)	93 sec	104 sec	≤ 45 sec
Beta-2-Glycoprotein IgG	92 SGU	21 SGU	≤ 20 SGU
Beta-2-Glycoprotein IgA	89 SAU	119 SAU	≤ 20 SAU
Anticardiolipin IgA	Not tested	> 150 APL	≤ 11 APL

Table 2 shows initial antiphospholipid antibody studies that were obtained 6 weeks prior to the patient’s admission (“Initial”), as well as these same studies during admission (“Follow-up after 6 weeks”). As shown, our patient had persistence of lupus anticoagulant as manifested by a prolonged PTT and hexagonal phase confirm, in addition to immunoglobulins against beta-2-glycoprotein.

Here, we present a patient with clinically significant mitral valve stenosis who developed CAPS after mitral valve

replacement surgery. This case clearly demonstrates the diagnostic challenge of CAPS, especially when it represents the initial manifestation of APS. Furthermore, it also illustrates CAPS as an immediate complication after cardiac valvular replacement, a phenomenon that has not been well-documented in the current literature.

2. CASE PRESENTATION

A 57-year-old Pakistani female presented with four days of worsening dyspnea on exertion, orthopnea, and cough pro-

ductive of blood-tinged sputum. She was admitted to an outside hospital and underwent diuresis for acute decompensated heart failure. She had been planned to have a mitral valve replacement (MVR), but she was ultimately referred to our facility to undergo this surgery earlier than expected given her recurrent symptoms and repeated hospital admissions.

Her past medical history was significant for severe mitral stenosis, stage III chronic kidney disease with an atrophic right kidney, and asymptomatic thrombocytopenia, thought to be secondary to immune-mediated thrombocytopenia (ITP). Of note, her obstetric history revealed that she had five spontaneous abortions that occurred between 8-12 weeks gestation. Furthermore, during her thrombocytopenia evaluation, she was found to have a positive lupus anticoagulant and beta-2 glycoproteins (see Table 2). However, she was not formally diagnosed with APS, and was not anticoagulated prior to admission.

Her initial vital signs were as follows: Blood pressure 120/70 mmHg, pulse 93/min, respirations 18/min, and oxygen saturation 95% on room air. Her physical exam was significant for a grade II diastolic murmur, but was otherwise unremarkable. Her mental status was at her baseline, and she was alert, awake, and oriented. She had no signs of gingival or mucosal bleeding, no petechial rashes, and no hepatosplenomegaly.

After her volume status was optimized, she underwent a mitral valve replacement on the 9th day of admission with a biological tissue valve. Her perioperative course was uncomplicated. However, her platelet count, which was 98,000/ μ l on the morning prior to surgery, had dropped to 59,000/ μ l immediately post-operatively, despite being transfused two packs of platelets in the operating room. The etiology of this refractory thrombocytopenia was not clearly defined, as a heparin-induced thrombocytopenia (HIT) panel was negative, and there was no clinical or laboratory evidence to support thrombocytopenic thrombotic purpura (TTP) or disseminated intravascular coagulation (DIC). Nonetheless, three days after surgery, the patient was started on eltrombopag, an oral thrombopoietin-receptor agonist which has been found to increase platelet counts in a dose-dependent manner in patients with refractory ITP.^[4] Despite being continued on oral eltrombopag at 50 mg daily, her platelet count dropped further to < 30,000/ μ l by post-operative day (POD) 7, at which point intravenous dexamethasone 40 mg was added.

In the following days, the patient began to complain of severe

7/10 epigastric abdominal pain, unexplained by imaging. In addition, her serum creatinine (SCr) trended up from 1.83 mg/dl on POD5 to 3.46 mg/dl on POD 7. Eltrombopag was discontinued because of her decline in renal function. Extensive evaluations for infectious and noninfectious causes of her clinical deterioration were unremarkable. She then developed an acute change in mental status, mostly manifested by confusion and changes in personality and behavior. Her multiple organ involvement prompted the consideration of CAPS. The patient had compromise of four organ systems with rapid symptom development over one week, and repeat antiphospholipid studies showed a persistence of antiphospholipid antibodies six weeks apart (see Table 2). She fit the diagnostic criteria for probable CAPS, and the decision was made to start both plasmapheresis and hemodialysis on POD 12.

Following the first treatment of plasmapheresis, her mentation improved to baseline and her abdominal pain subsided. She was started on a heparin infusion with bridge to warfarin on day 4 of plasmapheresis. Her platelet count showed a dramatic improvement, from 27,000/ μ l to 176,000/ μ l after 5 treatments of plasmapheresis (see Figure 1). A renal biopsy was encouraged to confirm the diagnosis of thrombotic microangiopathy, but the patient and her family declined.

As shown in Figure 1, our patient had a significant drop in her platelet count after her mitral valve replacement. Furthermore, she began to have manifestations of multi-organ small vessel injury, including confusion, abdominal pain, and worsening renal failure. She was started on plasmapheresis, which led to a dramatic recovery in her platelet count. In addition, her nonspecific symptoms of abdominal pain and confusion resolved. She did, however, require hemodialysis through the duration of the admission and several months post-discharge. Once her platelet count was stable, she was started on anticoagulation with a heparin infusion, which was transitioned to warfarin. In addition, she was transitioned to steroids for immunosuppression.

Once her platelet counts stabilized, she was started on intravenous methylprednisolone 1,000 mg for 3 days, and then transitioned to oral prednisone daily 1 mg/kg daily until outpatient follow-up. She remained dialysis-dependent for oliguric renal failure secondary to CAPS for four months after discharge. At 10-month follow-up, she was maintained on oral warfarin for anticoagulation, transitioned off of oral prednisone, and has had no further complications since her initial catastrophic event.

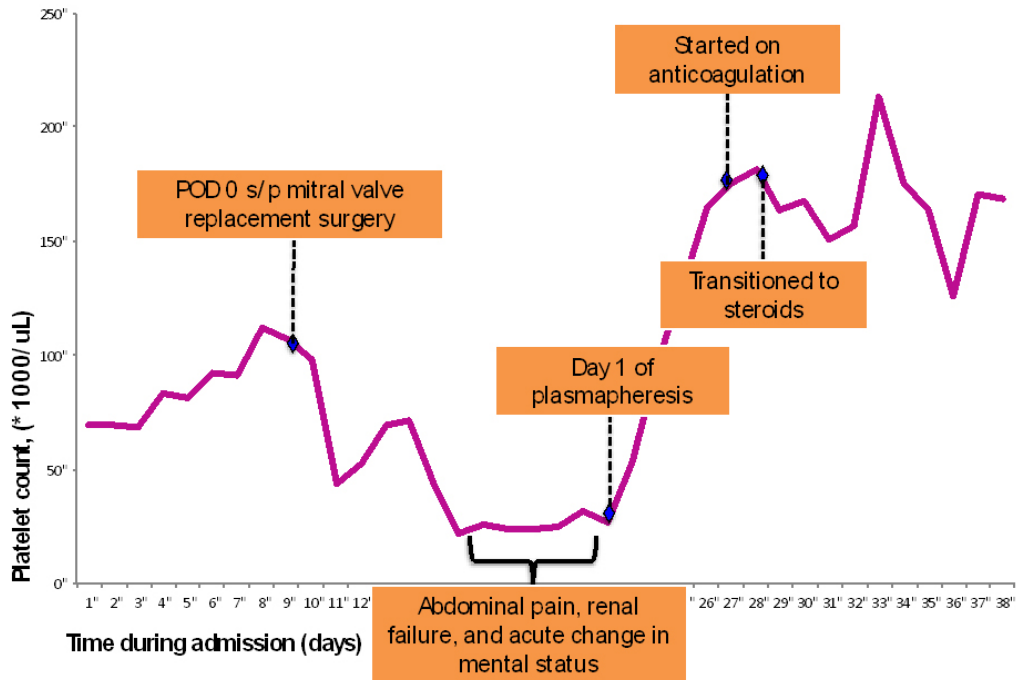


Figure 1. Clinical timeline of events and response to therapy

3. DISCUSSION

The management of CAPS must have three objectives: prompt treatment and awareness of precipitating factors, prevention of further thrombotic events with anticoagulation, and suppression of the immune response and cytokine storm.^[2,5] The therapies for CAPS mainly consist of anticoagulation and immunomodulation.^[5-7]

There are several proposed mechanisms and precipitating factors for the development of CAPS. Infection, trauma, and invasive procedures/surgeries are thought to be the leading triggers.^[2,5] In major surgeries, the postulated mechanism for the development of CAPS is excessive cytokine production, which alters endothelial cell function and leads to up-regulation of the coagulation cascade.^[5]

In the CAPS registry created by Cervera *et al.*, 35 of 282 cases (12.4%) of CAPS were thought to be precipitated by surgery. Of these cases, 31.4% (11/35) involved gynecological surgeries, while 25.7% (9/35) involved intra-abdominal surgeries.^[9-16] There were no cases of CAPS in the CAPS registry that involved intra-cardiac surgery.

Although there is increased morbidity and mortality among patients with known APS undergoing cardiac valvular surgery, there is currently scarce data to suggest that CAPS is a frequent complication. Many patients with pre-existing APS undergoing valvular replacement suffer from large vessel (arterial and venous) thromboembolism rather than the innumerable small vessel occlusions seen in CAPS. In a meta-

analysis conducted in 2008 by Gorki *et al.*, 57 patients with either primary or secondary APS who underwent valvular surgery were evaluated for post-operative complications. Ten patients suffered cardiac events (myocardial infarction, acute heart failure, cardiac tamponade), 10 patients suffered neurological events (seizures, transient ischemic attacks, stroke), 4 patients suffered peripheral or pulmonary embolism, and only one patient was reported to suffer from CAPS, manifesting as multiple organ failure, immediately after valve revision.^[17]

Considering that many patients with APS have co-existing valvular heart disease requiring surgical management, it is interesting that there is a relative paucity of CAPS cases that have been reported following valvular surgeries in such patients. Heavy heparinization during cardiopulmonary bypass (CPB) could possibly explain this observation. Several studies published in the field of cardiothoracic surgery have sought to determine the optimal methods of perioperative heparin and protamine administration to decrease the incidence of complications. One study observed that empirically doubling the baseline activated clotting time (ACT) in patients with APS, followed by prompt initiation of therapeutic anticoagulation post-operatively, led to decreased morbidity and mortality.^[18] Other studies have investigated the utility of pre-operative titration of the ACT, use of other anticoagulants such as bivalirudin, and administration of less protamine.^[19-21] To our knowledge, there has not been any large-scale clinical trial to determine the most effective anti-

coagulation strategy in patients with APS undergoing cardiac surgery with CPB.

As mentioned previously, CAPS has a high mortality if left untreated; in addition, because of this syndrome's tendency to closely mimic other conditions, there can be a delay in the diagnosis. The most common causes of death in CAPS include stroke, cardiac infarction, pulmonary hemorrhage and/or ARDS, infection, and multi-organ failure.^[2,5] Erkan *et al.* showed that 66% of patients who survived the initial catastrophic event remained free of symptoms with anticoagulation for an average of 62.7 months.^[8] Several patients continued to have manifestations of APS, despite therapy with immunomodulation and anticoagulation, and a

very small percentage of patients experienced repeat catastrophic events.^[8]

Our case illustrates the importance of recognizing and reporting cases of CAPS, thus allowing the medical community to appreciate the variable and sometimes vague presentations of this highly fatal disease. It also stresses the importance of considering CAPS in patients who show signs of rapid clinical decline and multiple organ system involvement following surgical procedures, particularly those patients with known APS.

CONFLICTS OF INTEREST DISCLOSURE

The authors have declared no conflicts of interest.

REFERENCES

- [1] Erkan D, Aguiar CL. Catastrophic antiphospholipid syndrome: how to diagnose a rare but highly fatal disease. *Ther Adv Musculoskel Dis.* 2013; 5(6): 305-314. PMID:24294304 <http://dx.doi.org/10.1177/1759720X13502919>
- [2] Asherson R, Cervera R, de Groot P, *et al.* Catastrophic antiphospholipid syndrome: international consensus statement on classification criteria and treatment guidelines. *Lupus.* 2003; 12: 530-534. PMID:12892393 <http://dx.doi.org/10.1191/0961203303lu394oa>
- [3] Stasi R, Rossi Z, Stipa E, *et al.* Helicobacter pylori eradication in the management of patients with idiopathic thrombocytopenic purpura. *Am J Med.* 2005; 118: 414-419. PMID:15808140 <http://dx.doi.org/10.1016/j.amjmed.2004.09.014>
- [4] Bussell JB, Cheng G, Saleh MN, *et al.* Eltrombopag for the Treatment of Chronic Idiopathic Thrombocytopenic Purpura. *N Engl J Med.* 2007; 357: 2237-2247. PMID:18046028 <http://dx.doi.org/10.1056/NEJMoa073275>
- [5] Asherson RA. Multiorgan failure and antiphospholipid antibodies: the catastrophic antiphospholipid (Asherson's) syndrome. *Immunobiology.* 2005; 210: 727-733. PMID:16325490 <http://dx.doi.org/10.1016/j.imbio.2005.10.002>
- [6] Ehresmann S, Arkfeld D, Shinada S, *et al.* A novel therapeutic approach for catastrophic antiphospholipid syndrome (CAPS) when conventional therapy with anticoagulants and steroids were unsuccessful. *Ann. Rheum. Dis.* 2004; 64.
- [7] Asherson RA, Cervera R, Piette JC, *et al.* Catastrophic antiphospholipid syndrome clues to the pathogenesis from a series of 80 patients. *Medicine.* 2001; 80: 355-377. PMID:11704713 <http://dx.doi.org/10.1097/00005792-200111000-00002>
- [8] Erkan D, Asherson RA, Espinoza G, *et al.* The long term outcome of catastrophic antiphospholipid syndrome survivors. *Ann. Rheum. Dis.* 2003; 62: 530-533. PMID:12759289 <http://dx.doi.org/10.1136/ard.62.6.530>
- [9] Spyropoulos AC. Membranous obstruction of the inferior vena cava and extensive bone necrosis associated with catastrophic antiphospholipid syndrome. *J Clin Rheumatol.* 1999; 5: 279-284. <http://dx.doi.org/10.1097/00124743-199910000-00008>
- [10] Maddison PJ, Thorpe C, Seale JRC, *et al.* Grand rounds from international lupus centres: "Catastrophic" antiphospholipid syndrome. *Lupus.* 2000; 9: 484-488. PMID:11035412 <http://dx.doi.org/10.1177/096120330000900702>
- [11] Kitchens CS. Thrombotic storm: When thrombosis begets thrombosis. *Am J Med.* 1998; 104: 381-385. [http://dx.doi.org/10.1016/S0002-9343\(98\)00061-8](http://dx.doi.org/10.1016/S0002-9343(98)00061-8)
- [12] Yahamoto T, Ito M, Nagata S, *et al.* Catastrophic exacerbation of the antiphospholipid syndrome after a lung adenocarcinoma biopsy. *J Rheumatol.* 2000; 27: 2035-2037.
- [13] Erkan D, Leibowitz E, Berman J, *et al.* Perioperative medical management of antiphospholipid syndrome: Hospital for special surgery experience, review of literature and recommendations. *J Rheumatol.* 2002; 29: 843-9. PMID:11950031
- [14] Lee J, Chang JE, Cho YJ, *et al.* Catastrophic antiphospholipid syndrome precipitated by bowel surgery. *Scan J Rheumatol.* 2002; 31: 110-111. <http://dx.doi.org/10.1080/03009740252937667>
- [15] Thuertl C, Althoefer C, Spyridonidis A, *et al.* Imaging findings in the rare catastrophic variant of the primary antiphospholipid syndrome. *Europ Radiology.* 2001. PMID:11870468
- [16] Cervera R, Rodríguez I, Espinosa G, *et al.* Registry of the "European forum on antiphospholipid antibodies" for patients with the "catastrophic" antiphospholipid syndrome. CAPS registry. Available from: <http://www.med.ub.es/MIMMUN/FORUM/CAPS.HTM>
- [17] Gorki H, Malinovski V, Stanbridge RDL. The antiphospholipid syndrome and heart valve surgery. *Eur J Cardio Thorac Surg.* 2008; 33: 168-18. PMID:18082413 <http://dx.doi.org/10.1016/j.ejcts.2007.11.004>
- [18] Sheikh F, Lechowicz A, Setlur R, *et al.* Recognition and management of patients with antiphospholipid antibody syndrome undergoing cardiac surgery. *J Cardiothorac Vasc Anesth.* 1997; 11: 764-6. [http://dx.doi.org/10.1016/S1053-0770\(97\)90173-7](http://dx.doi.org/10.1016/S1053-0770(97)90173-7)
- [19] East CJ, Clements F, Mathew J, *et al.* Antiphospholipid syndrome and cardiac surgery: management of anticoagulation in two patients. *Anesth Analg.* 2000; 90: 1098-101. <http://dx.doi.org/10.1097/00000539-200005000-00017>
- [20] Cain RL, Spiess BD, Nelson M, *et al.* Bivalirudin anticoagulation for a patient with hypercoagulable immune syndromes undergoing mitral valve surgery. *Ann Thorac Surg.* 2006; 81: 2308-10. PMID:16731183 <http://dx.doi.org/10.1016/j.athoracsur.2005.08.033>
- [21] Massoudy P, Cetin SM, Thielmann M, *et al.* Antiphospholipid syndrome in cardiac surgery-an underestimated coagulation disorder? *Eur J Cardiothorac Surg.* 2005; 28: 133-7. PMID:15982596 <http://dx.doi.org/10.1016/j.ejcts.2004.12.062>