

## ORIGINAL ARTICLES

# Trans umbilical laparoscopic access during laparoscopic procedures

Roger Pozzo, Rodrigo Arrangoiz\*, Fernando Cordera, Eduardo Moreno, Enrique Luque-De-León, Manuel Muñoz, Fernando Lambreton

*Department of Surgery, Centro Médico ABC, Mexico*

**Received:** September 7, 2016

**Accepted:** November 13, 2016

**Online Published:** November 21, 2016

**DOI:** 10.5430/css.v3n1p1

**URL:** <http://dx.doi.org/10.5430/css.v3n1p1>

## ABSTRACT

**Introduction:** The advent of laparoscopic surgery is one of the most important advances in modern surgical technique. In order to perform laparoscopic procedures it is necessary to first access the peritoneal cavity and establish a pneumoperitoneum. The placement of the first port remains a critical step in laparoscopic surgery. In order to minimize complications associated with placement of this first trocar, several techniques have been reported. We describe a surgical technique that has been developed by our surgical group that provides a quick, safe, and reliable initial access to the peritoneal cavity that is accompanied by excellent functional and cosmetic results.

**Methods:** Retrospective cohort of patients who underwent various laparoscopic procedures by our surgical group using our modified open technique for accessing the peritoneum from January 2000 to September 2012. We excluded patients who had a prior midline laparotomy with involvement of the umbilicus, but not those with previous transverse umbilical herniorrhaphies.

**Results:** We identified 963 patients (M = 419; F = 544) in the study period. Average age of the patients was 40 years (range: 15-83). Median follow up of 2.8 years (range: 6-144 months). No complications occurred during the insertion of the first trocar. A physiologic defect was identified in the umbilical region in all patients who had no history of previous abdominal surgery in that region. Postoperative complications occurred in 39 patients (4.0%). The most common complication was a postoperative seroma, which occurred in 24 patients (2.4%). Superficial surgical site infection occurred in eight patients (0.84%), hematoma in two patients (0.21%), and incisional hernias in the umbilical port site in five patients (0.51%). The average time to access the peritoneal cavity was 1.5 minutes (range: 1-7).

**Conclusions:** We describe a modified open technique for accessing the peritoneal cavity through a small congenital umbilical defect that is almost universally present. This technique is quick, safe, reliable, simple, and easy to learn. It is associated with minimal morbidity and has excellent cosmetic results. Based on our experience, we believe that this method provides surgeons with an effective and safe way to insert the first trocar and we recommend it as a routine procedure to access the peritoneal cavity for abdominal laparoscopic surgery.

**Key Words:** Laparoscopy, Open technique, Complications

---

## 1. INTRODUCTION

In laparoscopic surgery safe access to the peritoneal cavity is the first step towards a successful laparoscopic procedure. One of the most critical moments of the laparoscopic ap-

proach is the access to the peritoneal cavity.<sup>[1]</sup> The most feared complications that may occur during the insertion of the first trocar are vascular and intestinal injuries.<sup>[2,3]</sup> The risk of complications when entering the abdominal cavity

\*Correspondence: Rodrigo Arrangoiz; Email: [rodrigo.arrangoiz@gmail.com](mailto:rodrigo.arrangoiz@gmail.com); Address: Department of Surgery, Centro Médico ABC, Mexico.

increases with a history of previous abdominal operations.

Among the various techniques for introducing the first trocar to achieve a pneumoperitoneum, two common methods are usually performed.<sup>[1-4]</sup> The first, also called the closed technique, requires the Veress needle, which is inserted in the abdominal cavity for carbon dioxide (CO<sub>2</sub>) insufflation followed by blind introduction of the first trocar. The second, also called open technique was first described by Hasson.<sup>[5]</sup> This technique begins with a small incision at the umbilical site and subsequently all layers of the abdominal wall are incised. The first trocar is then inserted under direct vision followed by gas insufflation.<sup>[6-8]</sup> We prefer the open technique because we feel that we have better visual control.

Despite the risk, the closed technique is still one of the most popular ways to achieve access to the peritoneal cavity.<sup>[9-11]</sup> This is mainly because the open technique requires more time to perform and there is an increased risk of gas leakage through incision.<sup>[12]</sup> Many different techniques have been described for creating the pneumoperitoneum utilizing the open technique.<sup>[6,8,9]</sup> We feel that the trans-umbilical approach, which we have been using for over a decade, is simple, safe and effective alternative. The aim of this paper is to report the result of our experience in the routine use of the open laparoscopic trans-umbilical approach.

## 2. MATERIAL AND METHODS

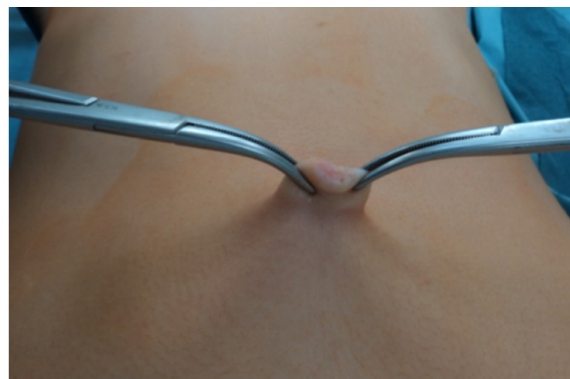Institutional review board approval was obtained for a retrospective analysis of all patients treated at our institution, American British Cowdery Medical Center, by our group, Sociedad Quirúrgica S.C, from January 2000 to September 2012. Inclusion criteria included all patients who underwent laparoscopic procedures with our modified open technique for creating the pneumoperitoneum with a minimum follow-up of 12 weeks. Exclusion criteria were patients undergoing midline laparotomy with distortion of the anatomy of the umbilicus. Patients with a history of an operation through a transverse umbilical incision and/or peri-umbilical region were included in the study. Electronic medical records were reviewed, and patient demographics, characteristics of their operation, postoperative complications, time to access the peritoneal cavity, date of discharge from the hospital, and date of last follow up visit were recorded.

### 2.1 Technique

All patients underwent general anesthesia and placed in supine position. The technique used is described as follows:

- Traction is applied from the bottom of the umbilical scar with two Kelly clamps and the umbilicus is everted (see Figure 1).

- A vertical trans-umbilical incision of 10 mm-15 mm is performed with a No. 15 scalpel (see Figure 2).
- Using electrocautery, we divide the subcutaneous tissues and, with blunt dissection, we identify the fascia at the midline.
- Due to the presence of a facial defect in all of our patients operated on without previous surgery at the umbilical region, we utilize this physiologic defect to insert our Kelly forceps through the defect and the fascia is divided under direct vision a few millimeters cephalad and a few millimeters caudally to achieve an incision so a 12 mm trocar can be introduced (see Figure 3).
- In patients with previous surgery at the umbilical region we modify our technique by applying two Backhaus towel clamps onto the fascia and dividing it under direct vision with the electro cautery.
- We then introduce two Farabeuf retractors to separate the fascia and expose the peritoneum, which is pulled upward with Kelly forceps and cut with Metzenbaum scissors.
- Maintaining the upward pull we introduce the blunt trocar under direct vision (see Figure 4).
- We use a 12 mm balloon trocar to try and prevent the leakage of gas through the wound.
- At the end of the procedure we expose the fascia with our Farabeuf retractors and it is closed with interrupted sutures (Ethibon # 0).
- The surgical wound is irrigated with saline solution and skin is closed using Monocryl 4-0 in a subcuticular fashion (see Figure 5).

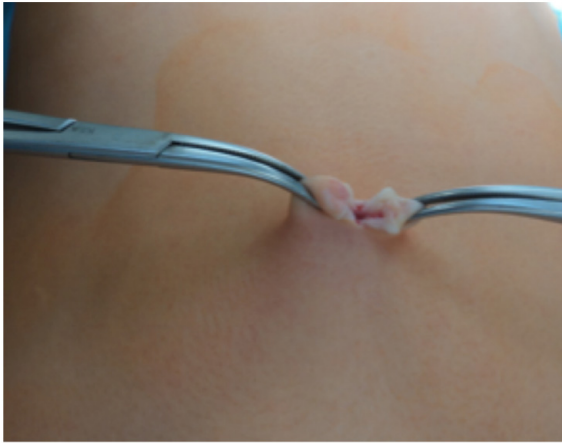


**Figure 1.** Elevation of the umbilicus with Kelly clamps

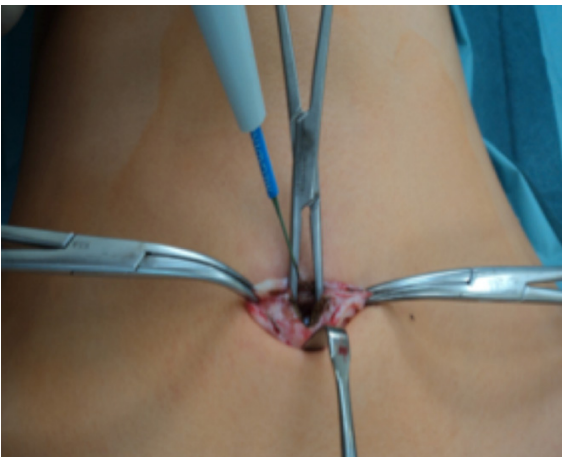
### 2.2 Patients

During the study period we identified a total of 963 patients that met our inclusion criteria of not having a midline laparotomy (M = 419; F = 544). The types of operations

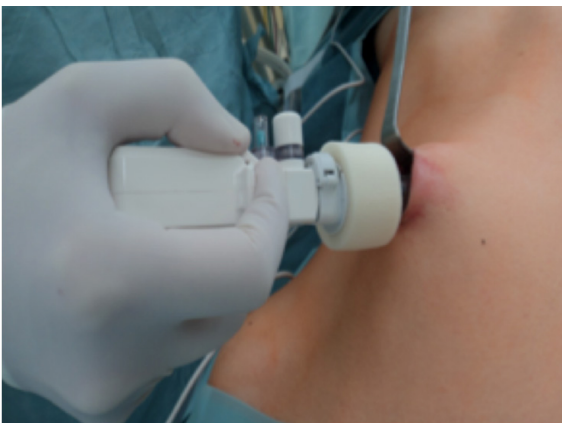performed were appendectomy, cholecystectomy, fundoplication, colectomy, splenectomy, and inguinal and abdominal wall hernioplasties.



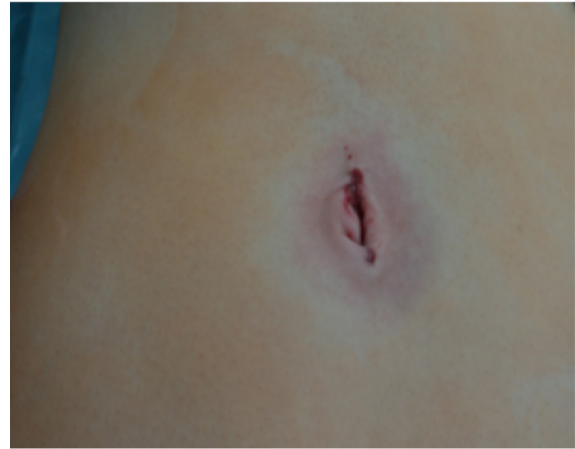**Figure 2.** Vertical 10 mm-15 mm incision of the umbilicus with a number 15 scalpel



**Figure 3.** Physiologic fascial defect of the umbilicus which is lengthened using electrocautery



**Figure 4.** Introduction of blunt trocar while maintaining elevation



**Figure 5.** Surgical wound is irrigated with saline solution and closed with a subcuticular Monocryl 4-0 suture

### 3. RESULTS

We identified 963 patients in the study period. Average age of the patients was 40 years (range: 15 to 83). The median follow up of our cohort was 33.6 months (range: 6 to 144 months). No complications occurred during the insertion of the first trocar. A physiologic defect was identified at the umbilical region in all patients who had no history of previous abdominal operations in that region. Postoperative complications occurred in 39 patients (4.0%) of which the main complication was postoperative seroma, which occurred in 24 patients (2.4%). Superficial surgical site infections occurred in eight patients (0.84%), hematoma occurred in two patients (0.21%), and incisional hernias at the umbilical port site in five patients (0.51%). The average time to access the peritoneal cavity was 1.5 minutes (range: 1 to 7 minutes).

### 4. DISCUSSION

For more than a decade, laparoscopic surgery has become the most commonly performed procedure in surgery around the world.<sup>[1]</sup> Many surgeons have surpassed the learning curve for most procedures and therefore major complications have been reduced significantly. Azevedo et al.<sup>[15]</sup> in a cohort of in 696,502 patients who underwent a laparoscopic procedure using the closed technique (Veress needle) to enter the abdominal cavity have reported an incidence rate of vascular and visceral injuries of 0.018% and of 0.0024%, respectively.

Currently the closed technique is the preferred technique among most laparoscopic surgeons despite the associated risks. This is due largely to successful personal experiences and the fact that the open technique has been linked to some technical difficulties such as increased time to access the peritoneal cavity compared to the closed technique and gas leakage through incision.<sup>[13-18]</sup> In a meta-analysis by Bonjer

et al.<sup>[19]</sup> vascular injuries occurred in 0.083% of patients using the closed technique and in 0.075% of patients using the open technique, while visceral injuries occurred in 0.048% of patients using the closed technique and in 0.0% using the open technique. The meta-analysis showed a tendency to eliminate visceral injuries and reduce the risk of major complications with the open technique.

The open technique was described by Hasson in 1971<sup>[5]</sup> and was recommended in patients with a previous laparotomy in whom they expected to find adhesions.<sup>[3,4,12]</sup> The major technical problem encountered was gas leakage through the incision resulting in modifications and the development of newer techniques derived from the original one.<sup>[16–20]</sup> Today, trocars have advanced designs; they are equipped with a security system capable of preventing the leakage of gas and the incidental extraction of the trocar.<sup>[20]</sup> The European Association of Endoscopic Surgery guidelines concluded that there is no available evidence to support any of the two techniques.<sup>[1]</sup> A recent analysis of 3,000 cases of open vs. closed entry techniques showed that the open technique has better outcomes in terms of major complications, which included failure to create pneumoperitoneum, emphysema extending up to the neck causing dyspnoea, bowel perforation, bladder perforation and mesenteric vascular injury (open vs. closed: 1.33% vs. 0.13,  $p < .001$ ).<sup>[20]</sup>

We describe a modification to the open technique with a trans umbilical incision, which provides a fast, secure, and effective way of entering abdominal cavity under direct vision. The technique uses the umbilicus, a region that had remained unused in this type of procedures for a long time.<sup>[21]</sup> Some

of the advantages of this method are that it does not require a long time to perform, it is safe and effective, and it can be used in many clinical situations, including previous abdominal operations.<sup>[22]</sup> In our series the surgical site infection rate was similar (0.84%) to that reported in the literature (0.6%).<sup>[23]</sup> Although speed of entry into the abdominal cavity was not the main outcome of the study, we show that this technique is simple to learn and perform, and, once mastered, it can be done promptly without delaying the operation.<sup>[24,25]</sup> Through the use of the open technique vascular and visceral injuries can be virtually eliminated, significantly improving patient safety.<sup>[26]</sup> Lastly, the cosmetic effect of an umbilical incision is believed to be superior, as the scar is partially hidden by the umbilicus itself when depressed into its natural position.

## 5. CONCLUSIONS

We describe a modified open technique for accessing the peritoneal cavity through a small congenital umbilical defect that is almost universally present. This technique is quick, safe, reliable, simple, and easy to learn. It is associated with minimal morbidity and has excellent cosmetic results. Based on our experience, we believe that this method provides surgeons with an effective and safe means to insert the first trocar and we recommend it as a routine procedure to access the peritoneal cavity for abdominal laparoscopic surgery.

## CONFLICTS OF INTEREST DISCLOSURE

The authors declare they have no conflicts of interest.

## REFERENCES

- [1] Neudecker J, Sauerland S, Neugebauer E, et al. The European Association for Endoscopic Surgery clinical practice guideline on the pneumoperitoneum for laparoscopic surgery. *Surgical Endoscopy*. 2002; 16(7): 1121–43. PMID: 12015619. <https://doi.org/10.1007/s00464-001-9166-7>
- [2] Perunovic RM, Scepanovic RP, Stevanovic PD, et al. Complications during the establishment of laparoscopic pneumoperitoneum. *Journal of Laparoendoscopic & Advanced Surgical Techniques Part A*. 2009; 19(1): 1–6. PMID: 19196086. <https://doi.org/10.1089/lap.2008.0236>
- [3] Munro MG. Laparoscopic access: complications, technologies, and techniques. *Current Opinion in Obstetrics & Gynecology*. 2002; 14(4): 365–74. <https://doi.org/10.1097/00001703-200208000-00002>
- [4] Rosen DM, Lam AM, Chapman M, et al. Methods of creating pneumoperitoneum: a review of techniques and complications. *Obstetrical & Gynecological Survey*. 1998; 53(3): 167–74. <https://doi.org/10.1097/00006254-199803000-00022>
- [5] Hasson HM. A modified instrument and method for laparoscopy. *American Journal of Obstetrics & Gynecology*. 1971; 110(6): 886–7. [https://doi.org/10.1016/0002-9378\(71\)90593-X](https://doi.org/10.1016/0002-9378(71)90593-X)
- [6] Vilos GA, Ternamian A, Dempster J, et al. Laparoscopic entry: a review of techniques, technologies, and complications. *Journal of obstetrics and gynaecology Canada: JOGC = Journal d'obstétrique et gynécologie du Canada: JOGC*. 2007; 29(5): 433–65. [https://doi.org/10.1016/S1701-2163\(16\)35496-2](https://doi.org/10.1016/S1701-2163(16)35496-2)
- [7] Inan A, Sen M, Dener C, et al. Comparison of direct trocar and veress needle insertion in the performance of pneumoperitoneum in laparoscopic cholecystectomy. *Acta Chirurgica Belgica*. 2005; 105(5): 515–8. PMID: 16315837. <https://doi.org/10.1080/00154458.2005.11679771>
- [8] Schäfer M, Lauper M, Krähenbühl L. Trocar and Veress needle injuries during laparoscopy. *Surgical Endoscopy*. 2001; 15(3): 275–80. PMID: 11344428. <https://doi.org/10.1007/s004640000337>
- [9] Schoonderwoerd L, Swank DJ. The role of optical access trocars in laparoscopic surgery. *Surgical Technology International*. 2005; 14: 61–7. PMID: 16525956.

- [10] String A, Berber E, Foroutani A, et al. Use of the optical access trocar for safe and rapid entry in various laparoscopic procedures. *Surgical Endoscopy*. 2001; 15(6): 570-573. PMID: 11591942. <https://doi.org/10.1007/s004640080056>
- [11] Ma L, Sun N, Liu X, et al. Organ-specific expression of Arabidopsis genome during development. *Plant Physiology*. 2005; 138(1): 80-91. PMID: 15888681. <https://doi.org/10.1104/pp.104.054783>
- [12] Merlin TL, Hiller JE, Maddern GJ, et al. Systematic review of the safety and effectiveness of methods used to establish pneumoperitoneum in laparoscopic surgery. *British Journal of Surgery*. 2003; 90(6): 668-679. PMID: 12808613. <https://doi.org/10.1002/bjs.4203>
- [13] Ballem RV, Rudomanski J. Techniques of pneumoperitoneum. *Surgical laparoscopy & endoscopy*. 1993; 3(1): 42-3. PMID: 8258070.
- [14] Sadhu S, Jahangir TA, Sarkar S, et al. Open port placement through the umbilical cicatrix. *Indian Journal of Surgery*. 2009; 71(5): 273-5. PMID: 23133171. <https://doi.org/10.1007/s12262-009-0069-5>
- [15] Azevedo JLMC, Azevedo OC, Miyahira SA, et al. Injuries caused by Veress needle insertion for creation of pneumoperitoneum: a systematic literature review. *Surgical Endoscopy*. 2009; 23(7): 1428-32. PMID: 19263124. <https://doi.org/10.1007/s00464-009-0383-9>
- [16] Barwijek AJ, Jakubiak T, Dziąg R. Use of the Hasson technique for creating pneumoperitoneum in laparoscopic surgery. *Ginekologia polska*. 2004; 75(1): 35-8. PMID: 15112471.
- [17] Lal P, Singh L, Agarwal PN, et al. Open port placement of the first laparoscopic port: a safe technique. *Jsls Journal of the Society of Laparoendoscopic Surgeons*. 2004; 8(4): 364-6. PMID: 15554282.
- [18] Lal P, Sharma R, Chander R, et al. A technique for open trocar placement in laparoscopic surgery using the umbilical cicatrix. *Surgical Endoscopy*. 2002; 16(9): 1366-70. PMID: 12296314. <https://doi.org/10.1007/s00464-001-8308-2>
- [19] Bonjer HJ, Hazebroek EJ, Kazemier G, et al. Open versus closed establishment of pneumoperitoneum in laparoscopic surgery. *British Journal of Surgery*. 1997; 84(5): 599-602. PMID: 9171741. <https://doi.org/10.1002/bjs.1800840506>
- [20] Taye M. Open Versus Closed Laparoscopy: Yet an Unresolved Controversy. *JCDR*. 2016; 10(2).
- [21] Lal P, Vindal A, Sharma R, et al. Safety of open technique for first-trocar placement in laparoscopic surgery: a series of 6,000 cases. *Surgical Endoscopy*. 2012; 26(1): 182-8. PMID: 21853393. <https://doi.org/10.1007/s00464-011-1852-5>
- [22] Lafullarde T, Van Hee R, Gys T. A safe and simple method for routine open access in laparoscopic procedures. *Surgical Endoscopy*. 1999; 13(8): 769-72. PMID: 10430681. <https://doi.org/10.1007/s004649901095>
- [23] Penfield AJ. How to prevent complications of open laparoscopy. *The Journal of reproductive medicine*. 1985; 30(9): 660-3. PMID: 2932552.
- [24] Esposito C. Transumbilical open laparoscopy: a simple method of avoiding complications in pediatric surgery. *Pediatric surgery international*. 1997; 12(2/3): 226-7. <https://doi.org/10.1007/BF01350014>
- [25] Moberg AC, Petersson U, Montgomery A. An open access technique to create pneumoperitoneum in laparoscopic surgery. *Scandinavian journal of surgery : SJS : official organ for the Finnish Surgical Society and the Scandinavian Surgical Society*. 2007; 96(4): 297-300.
- [26] Compeau C, McLeod NT, Ternamian A. Laparoscopic entry: a review of Canadian general surgical practice. *Canadian Journal of Surgery*. 2011; 54(5): 315-20. PMID: 21774882. <https://doi.org/10.1503/cjs.011210>