

CASE REPORTS

Salvage repair of rare iatrogenic bilateral ureteral injury after hysterectomy

Xiao Han¹, Pramit Khetrpal², David T. Consigliere³, Ho Yee Tiong*³

¹Department of Medicine, Yong Loo Lin School of Medicine, Singapore, Singapore

²University College London, UCL Medical School, London, United Kingdom

³Department of Urology, National University Hospital, Singapore, Singapore

Received: July 21, 2015

Accepted: September 16, 2015

Online Published: September 22, 2015

DOI: 10.5430/css.v2n1p23

URL: <http://dx.doi.org/10.5430/css.v2n1p23>

ABSTRACT

Ureteric injury is a well-documented complication of gynecological surgery, however, bilateral ureteric injuries are rarely encountered and there is no consensus on the management of such complex injuries. We present our successful management of iatrogenic bilateral ureteric injuries in a patient after failed primary endourological surgery and attempted open repair. Our patient is a thirty-five years-old woman who sustained bilateral ureteral injury after open radical hysterectomy to treat a squamous cell carcinoma of her uterus. She subsequently became reliant on bilateral ureteral stents following a failed open surgical repair of her left ureter. Upon evaluation, retrograde pyelogram showed bilateral ureteral strictures with hydronephrosis and ureteroscopy could not be passed beyond the tight strictures in the ureters following removal of double-J stents. Open bilateral repair of ureters aims to achieve tension-free bilateral ureteroneocystostomies with a unilateral right psoas hitch. We discussed the adaptations of conventional technique involving tunneling of the left ureter underneath the sigmoid mesentery. She recovered well and was stable on discharge. Upon follow-up in clinic one year later, hydronephrosis resolved completely with conserved renal function. Therefore, we demonstrated and outlined the principles in our successful approach and showed that it is feasible to treat bilateral ureteral injuries following hysterectomy with open repair in spite of unsuccessful primary endourological surgery and attempted open repair.

Key Words: Bilateral ureteric injury, Psoas hitch, Ureteroneocystostomy

1. INTRODUCTION

Ureteric injury is a documented complication of gynecological surgeries with a range of therapeutic surgical options available. However, bilateral ureteric injuries can be a reconstructive challenge because ureteral length is often insufficient for direct anastomosis or reimplantation on both sides. There is currently a paucity of reported evidence outlining the management of these issues. This case report highlights a patient who underwent successful bilateral ureteroneocystostomies with psoas hitch to remedy iatrogenic bilateral

ureteric injuries after failed primary endourological surgery and attempted open repair.

2. CASE PRESENTATION

A 35-year-old lady was diagnosed with well-differentiated squamous cell carcinoma of T1b1N0M0 (FIGO staging) and subsequently underwent an open radical hysterectomy with a right salpingo-oophorectomy at an overseas hospital, on February 2010. She returned to the hospital with vaginal urine leak and bilaterally injured ureters that were identified

*Correspondence: Ho Yee Tiong; Email: cfsthy@nus.edu.sg; Address: 5 Lower Kent Ridge Road, Singapore.

on computer tomography (CT) urography (see Figure 1). At that time, double J ureteric stents were placed but when she was reviewed 3 months later, the strictures did not show signs of resolution on retrograde pyelogram. Open repair of the left ureter was attempted at the time but was again unsuccessful and she remained dependent on bilateral ureteric stents.

In August 2010, she came to National University Hospital in Singapore for a second opinion. She was asymptomatic at that time; with no hematuria, loin pain or signs of infection. Examination revealed a Pfannenstiel scar and a left iliac fossa Gridiron's scar. Her kidneys were not ballotable.

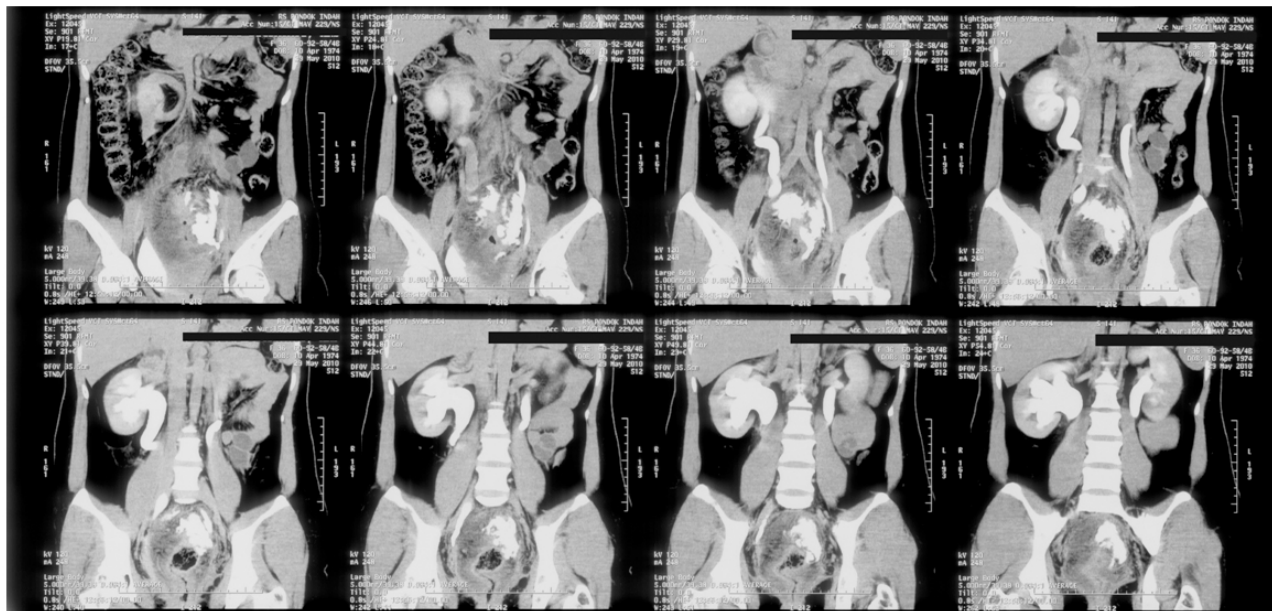


Figure 1. Bilaterally injured ureters on CT Urogram, with hydronephrosis and dilated ureters

In the first instance, she was examined under anesthesia and retrograde pyelogram was performed bilaterally. Ureteric strictures with hydronephrosis were still present bilaterally and after removing the double-J stents, ureteroscopy could not pass beyond the tight ureteral strictures. Urea and creatinine levels were 5.3 mmol/L and 63 μ mol/L respectively at baseline. After counseling, she was scheduled for surgical bilateral ureteric repair two days later after retrograde stents were replaced.

Surgical procedure

The procedure was performed under general anesthesia with the patient in the supine position. A midline laparotomy was performed. Extensive intra-peritoneal adhesions involving small bowel and the abdominal wall were identified, so adhesiolysis was performed. The bowel was packed cranially to allow for ureteric dissection, starting with the right ureter. The in-situ stent facilitated the identification of the ureter, and it was dissected distally to access the stenosed area and divided proximally to the stricture while identifying and preserving its blood supply. The left ureter was then similarly dissected but adhesions were more significant due to prior attempted repair. The mobilized left ureter was tunneled to the right side through a created window within the

sigmoid colon mesentery. Both ureters were divided above the stricture levels and confirmed to be healthy with good blood supply. With the ureters spatulated and stented, the bladder was mobilized down to endo-pelvic fascia anteriorly by ligating the superior vesical pedicle and the fascia incised to facilitate adequate mobilization. Separate tunneled ureteroneocystostomies were performed over the bladder dome ensuring both anastomoses were tension-free with a unilateral right Psoas Hitch^[1] (see Figure 2). A second layer closure of the anastomoses was performed with 3/vicryl sutures, creating an extravesical anti-reflux tunnel as per Lich Gregoir.^[2] A drain was inserted prior to closure. Specimens of left distal ureter and abdominal wall collection were sent off for histological assessment intra-operatively but no malignant pathology was found. The patient was discharged 6 days post-operatively after transient post-operative ileus and two febrile episodes that resolved completely. At her review appointments two months after surgery, the hydronephrosis was resolving on ultrasound. The stents were removed and patient had no subsequent symptoms. A follow up CT urogram 6 weeks after stent removal showed flow of contrast down both ureters with no obstruction (see Figure 3). Patient was seen one year post-operatively for review. Hy-

dronephrosis had resolved completely and patient was well with preserved renal function.

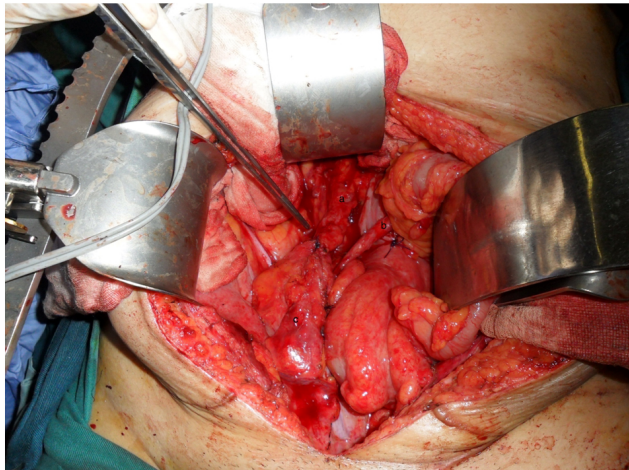


Figure 2. Intra-operative photo of bilateral ureteric implantation. a: Right ureter; b: Left ureter; c: Bladder

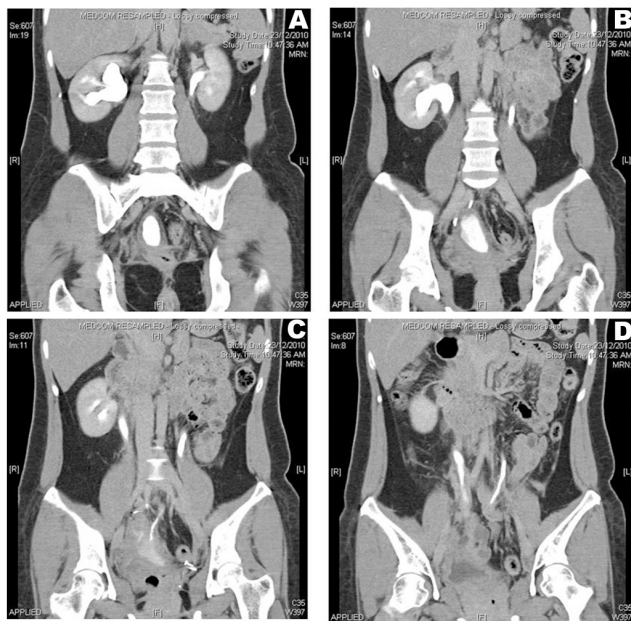


Figure 3. Follow-up CT Urogram 6 weeks after stent removal; Flow of contrast down both ureters with no obstruction demonstrated

A-B: Pyelogram showing resolution of hydronephrosis; C-D: Ureteric phase showing resolution of hydroureter

3. DISCUSSION

Surgery adjacent to ureters as is the case in hysterectomy may result in bilateral ureteric injury. All necessary precautions should be taken intra-operatively and a high index of suspicion is required in monitoring the patient post-operatively to pick up early symptoms suggestive of bilateral injury^[3]

as it is often delayed recognition that results in significant morbidity. Despite adequate care and consideration, it is easy to compromise the blood supply leaving a de-vascularized segment, which subsequently stenoses and presents with complications post-operatively. This case discusses the management of reconstructive challenges of bilateral ureteric repair.

The management of ureteric injury depends on the patient's condition, disease factors such as extent and location of the injury and surgeon factors. Adequate management demands a multitude of technical skill and expertise in dealing with both operative challenges and medico-legal pressures that surround patients with iatrogenic injury. Although recent novel techniques with reasonable outcomes were reported, current results are limited and there is no obvious consensus on bilateral ureteral repair due to a poverty of evidence supporting one particular treatment modality.^[4,5] In addition, endourological techniques and equipment has been increasingly utilized in managing post-operative ureteric injuries.^[6,7]

In the above case, we elected for an open approach because an important consideration in bilateral ureteric injury is to preserve renal function. For bilateral injuries, there is scarce evidence comparing open reconstruction and endourological methods such as laparoscopic and robotic ureteral reconstruction.^[7-9] In particular, there were reports that deemed bilateral ureteric injury as an indication to forgo endourological treatment options and move on to open reconstruction directly.^[10] Additionally, this is a salvage repair, which is best managed open, because of the patient's bilateral persistent strictures despite stenting and prior unsuccessful attempted open repair.

The psoas hitch ureteral re-implantation is the initial approach when a primary ureteroneocystostomy cannot be performed without tension. It is also associated with good long-term outcomes.^[11] The key to a successful psoas hitch ureteroneocystostomy are: (1) mobilization of the bladder with fixation above the iliac vessels to guarantee a tension-free ureteric anastomosis; (2) formation of an adequate submucosal tunnel to prevent vesico-ureteric reflux; (3) Implantation of the ureter into an immobilized part of the bladder to prevent kinking during filling and emptying of the bladder.^[5,12,13] While these are standard principles and practice for unilateral psoas hitch, bilateral ureteric injuries, being rare^[13] and more complex, pose a challenging reconstructive problem. To tackle this, the conventional approach to surgical management of unilateral injury may need to be adapted to tackle cases of bilateral injury. Close observation is required to minimize further loss of renal function and to avoid uro-sepsis.

Although open repair is hindered by the issue of performing bilateral bladder reconfiguration by psoas hitch or Boari flap, we managed to overcome this by mobilizing the left ureter and delivering it through the sigmoid colon mesentery to the other side, allowing separate implantation of both injured ureters into the same bladder flap. A similar technique to what was described in our surgical procedure was utilized successfully by Shaw *et al.*^[14] It is conceivable that if necessary, a unilateral Boari flap reimplantation with crossing of one of the ureters is also possible if the ureteric injury levels were higher.

4. CONCLUSION

Ureteral reconstruction in the setting of bilateral ureteric injury is a difficult surgical challenge due to the complex situation it poses for the surgeon, who must ensure a good tension-free despite restrictions in ureteral length and anatomy. Herein, we have demonstrated and outlined principles of our technique to successfully achieve a tension-free repair to remedy bilateral ureteric injuries by making modifications to the conventional techniques of ureteric repair. This proved effective and feasible in our case of a patient who sustained iatrogenic bilateral ureteric injuries after failed primary endourological surgery and attempted open repair.

REFERENCES

- [1] Stein R, Rubenwolf P, Ziesel C, *et al.* Psoas hitch and Boari flap ureteroneocystostomy. *BJU international*. 2013; 112: 137-155. PMID: 23759011. <http://dx.doi.org/10.1111/bju.12103>
- [2] Riedmiller H, Gerharz EW. Antireflux surgery: Lich-Gregoir extravesical ureteric tunnelling. *BJU international*. 2008; 101: 1467-1482. PMID: 18454801. <http://dx.doi.org/10.1111/j.1464-410X.2008.07683.x>
- [3] Abboudi H, Ahmed K, Royle J, *et al.* Ureteric injury: a challenging condition to diagnose and manage. *Nature reviews. Urology*. 2013; 10: 108-115. PMID: 23318355. <http://dx.doi.org/10.1038/nrurol.2012.254>
- [4] Chen CL, Tang SH, Cha TL, *et al.* Combined Y-shaped common channel transureteroureterostomy with Boari flap to treat bilateral long-segment ureteral strictures. *BMC Res Notes*. 2014; 7: 550. PMID: 25138268. <http://dx.doi.org/10.1186/1756-0500-7-550>
- [5] Engel O, Rink M, Fisch M. Management of iatrogenic ureteral injury and techniques for ureteral reconstruction. *Curr Opin Urol*. 2015; 25: 331-335. <http://dx.doi.org/10.1097/mou.0000000000000175>
- [6] Rassweiler JJ, Gozen AS, Erdogru T, *et al.* Ureteral reimplantation for management of ureteral strictures: a retrospective comparison of laparoscopic and open techniques. *Eur Urol*. 2007; 51: 512-522; discussion 522-513.
- [7] Komninos C, Koo KC, Rha KH. Laparoendoscopic management of midureteral strictures. *Korean J Urol*. 2014; 55: 2-8. PMID: 24466390. <http://dx.doi.org/10.4111/kju.2014.55.1.2>
- [8] Fifer GL, Raynor MC, Selph P, *et al.* Robotic ureteral reconstruction distal to the ureteropelvic junction: a large single institution clinical series with short-term follow up. *Journal of endourology / Endourological Society*. 2014; 28: 1424-1428. PMID: 25230048. <http://dx.doi.org/10.1089/end.2014.0227>
- [9] Do M, Kallidonis P, Qazi H, *et al.* Robot-assisted technique for boari flap ureteral reimplantation: is robot assistance beneficial? *Journal of endourology / Endourological Society*. 2014; 28: 679-685.
- [10] Mendez R, McGinty DM. The management of delayed recognized ureteral injuries. *The Journal of urology*. 1978; 119: 192-193. PMID: 633474.
- [11] Wenske S, Olsson CA, Benson MC. Outcomes of distal ureteral reconstruction through reimplantation with psoas hitch, Boari flap, or ureteroneocystostomy for benign or malignant ureteral obstruction or injury. *Urology*. 2013; 82: 231-236. PMID: 23642933. <http://dx.doi.org/10.1016/j.urology.2013.02.046>
- [12] Burks FN, Santucci RA. Management of iatrogenic ureteral injury. *Ther Adv Urol*. 2014; 6: 115-124. PMID: 24883109. <http://dx.doi.org/10.1177/1756287214526767>
- [13] Brandes S, Coburn M, Armenakas N, *et al.* Diagnosis and management of ureteric injury: an evidence-based analysis. *BJU international*. 2004; 94: 277-289. PMID: 15291852. <http://dx.doi.org/10.1111/j.1464-410X.2004.04978.x>
- [14] Shaw MB, Tomes M, Rix DA, *et al.* The management of bilateral ureteric injury following radical hysterectomy. *Adv Urol*. 2008; 524919. <http://dx.doi.org/10.1155/2008/524919>