

ORIGINAL ARTICLES

Minimally invasive surgical treatment of tumors and metastases of the spine by plasma field therapy (Cavity-Coblation method)

Dzmitry Dabravolski *^{1,2}, Jan Eßer¹, Andreas Lahm^{1,3}, Harry Merk¹

¹ Department of Orthopaedics and Orthopaedic Surgery, Ernst-Moritz-Arndt University Greifswald, Greifswald, Germany

² Center for Orthopaedics and Spinal Surgery Fichtelgebirge, Marktredwitz, Germany

³ Tumor Center, Maria Hilf Clinics Mönchengladbach, Academic Teaching Hospital of the RWTH Aachen, Mönchengladbach, Germany

Received: December 14, 2015

Accepted: February 17, 2016

Online Published: February 22, 2016

DOI: 10.5430/css.v2n2p10

URL: <http://dx.doi.org/10.5430/css.v2n2p10>

ABSTRACT

Background: Tumours and metastases of the spine are extremely stressful for patients. A radical surgery of metastases of the spine is not possible in many cases. Especially higher risk elder multimorbid patients are at risk. The therapeutic goals are always: small invasiveness, high efficiency of tumour removal, fracture repositioning, stabilisation, pain reduction, improving the patient's life quality. The specialness and difficulties of the diagnosis and therapy with the Cavity/Coblation-method the operative technique, results of the treatment of more than 274 patients with vertebral body tumours/metastases is going to be presented.

Materials and methods: Patients: Patients of every age with destruction were treated: with osteolysis, Fractures of the spine caused by spinal tumours and metastases. Diagnosis preoperatively was evaluated through X-Ray, MRT, CT, complete body PET, histology. Cavity/Coblation method: The tumour tissue resection in the vertebra was carried out by the plasma field (T 42°C, cold energy) over the percutaneous transpedicular or extrapedicular access and was followed by vertebroplasty or balloon kyphoplasty with PMMA bone cement. This was followed up with clinical and radiological examinations, including data concerning pain and improvement of life quality after 2, 14 days as well as 3, 6, 12, 24, 36, 48 and 60 months postoperatively.

Results: Within 6 years (03/08-04/14) more than 274 patients (171 female, 103 male, age range of 31-92 y. old average age of 65.7) or 895 vertebral bodies with tumours or metastases were treated. In 61 cases of 274, dorsal percutaneous instrumentation und straightening was an additional treatment. A small amount of blood loss and a very low complication rate was recorded. Postoperatively was shown by all patients an obvious reduction of pain, increase in life quality, satisfaction with the operative result, rapid mobilization was possible as well as the immediate radiation and chemotherapy for reduction of the local tumour recurrence rate. The complications were as follows: in 39 cases of 274 a cement leakage occurred laterally or in the intervertebral disc space without clinical relevance. 194 patients (105 women, 89 men) are now deceased due to tumour manifestations.

Conclusions: Coblation/Cavity has shown itself to be a safe, minimal invasive procedure with good short and long term results, a low complication rate, blood loss and short surgery times. The total local recurrence rate for all patients with spine metastases in the study was in 35 from 250 cases/patients with metastasen or only in 14.0%. Following things are important: a comprehensive diagnostic including tumour staging, correct indication, prognostic assessment and precise surgical technique. The method bears much promise for the future.

Key Words: Tumours and metastases of the spine, Cavity, Coblation, Minimal invasive surgery, Kyphoplasty, Vertebroplasty, Plasma field

*Correspondence: Dzmitry Dabravolski; Email: dimdobrow@mail.ru; Address: Center for Orthopaedics and Spinal Surgery Fichtelgebirge, Wölsauerhammer 50, 95615 Marktredwitz, Germany.

1. INTRODUCTION

The treatments of tumours and metastases of the spine area have advanced considerably in the past centuries. However, many patients with multiple metastases with bone destruction, especially osteolyses and fractures in multiple vertebral bodies or other organs were limited to traditional therapeutic methods such as chemotherapy and possibly radiation, pain management *etc.*

Traditionally recognised methods are cryotherapy, thermotherapy or laser therapy and radiofrequency. (1) Cryotherapy operates at a very low temperature, is very labour intensive, is unable to remove all metastatic tissue completely and is highly likely to damage healthy tissue.^[1,2] (2) Thermo/laser therapy operates at higher temperatures, locally at 500°C-600°C and has considerable damage potential to healthy tissue;^[3,4] (3) Radiofrequency, for example with Rita Starburst™ MRI device, is operated with radiofrequency current, generates a very high temperature (more than 400°C) to damage tumour cells, is not able to fully destroy tumours/metastases and is also able to damage surrounding healthy tissues, nerves and vessels.^[2,5,6]

The execution of a radically open and lengthy operations for solitary metastases, such as the anteriorly and posteriorly fusions with vertebral body replacement, are linked to considerable intra-operative and postoperative risks. Examples of such risks are massive bleeding at a larger access, tumour resection, increased injury risk for blood vessels, nerves as well as wound healing disturbance and considerable infectious risk due to large contamination area and long operation times. Many different interoperative and postoperative complications, such as loosening and fractures of the osteosynthetic material and decompensation of neighbouring spine segments are very frequent.^[7-10]

Furthermore, there are contraindications for larger operative procedures in the spinal area for many patients with a reduced general condition. Especially high-risk patients such as patients with cardiopulmonary limitations make longer operational times and blood loss impossible, in particular when considering the questionable success of large invasive procedures. Above all, in both curative as well as palliative situations, the goals of the operative procedure are: a low traumatism of the soft tissue and bones through a minimal invasive technique, the reduction of blood loss, maintenance of stability of the vertebra and the spinal segment, adjusting the deformation or repositioning the compressions fracture, the decompression and expansion of the spinal canal with possibly complete removal of tumor tissue, prevention of vertebral body fracturing. Of utmost importance is the reduction of pain, as well as the improvement of life quality.

The correct indication and choosing the correct therapeutic method are very important for the proper treatment of metastases of the spine. The correct therapy always has to be determined on a case by case basis, depending on different criteria and parameters (clinical, radiological, histopathological, *etc.*). The recognised Score-systems (such as, but not limited to Tokuhashi-Score, Karnofsky-Index, Tomita-Score) are helpful to determine for each case the type and extent of the method -palliative or radically chirurgical tumour resection *etc.*^[9,11,12]

To optimise and improve the care of patients with multiple metastases and vertebral body destruction, our clinic successfully uses the recent and modern minimal invasive Coblation/Cavity method. So far, Coblation has only been used in a relatively small number of cases, in particular in the United States of America, Japan and France. In Germany, this method has been used for the spine in very few clinics, occasionally also for arthroscopy and in the Otorhinolaryngology.^[13,14] Not only does the removal of tumour tissue result in a cavity for cement, but all tumour cells are also destroyed and evaporated. Through the application of the plasma field, molecular bridges in the tumour are broken up, and the molecules start denaturation that leads to their transition to gas.^[2,15-17] The advantages are remarkable: through the creation of room, as well as the simultaneous coagulation and removal of the tumour using cold energy (locally around 42°C), the bone cement can be added without pressure. The risks of extravasation and tumour spread are decreased considerably. Other risks, especially blood loss and complications, are decreased and the OP times are considerably shorter.^[18,19]

The Cavity/Coblation method has significant advantages and differences to other long-established operational methods – vertebroplasty and kyphoplasty. In vertebroplasty the cement usually leaks around the tumour and the tumour is not substantially made smaller.^[20] In balloon kyphoplasty^[21-23] the balloons creates only a cave and the tumour cells are only pushed to the side, which increases the risk of tumour spread to blood vessels. Even in the radiofrequency kyphoplasty^[24-27] is the tumor not removed and only deported by the bone cement to the side, where there is also the risk of tumor spread through the blood vessels. In both methods occurs no removal of the tumour tissue.^[22,23,26-28] In Coblation, the controlled ablation, is done with a pre-bent plasma sonde. The tumour tissue is dissolved without thermal effect at very low temperatures through plasma field energy.

The purpose of this paper and clinical trial was above all to examine and expand the value and the possibilities and limits of applying the percutaneous Coblation/Cavity method via

plasma field followed by vertebro-/kyphoplasty to the spine. The second and very important task was to improve the therapy of tumours and metastasis of the spine through the combination of Cavity/Coblation with other procedures such as chemotherapy, radiation, additional dorsal minimal invasive percutaneous stabilisation and straightening through fixture of internal, open minimally invasive decompression. Included in this task is the improvement and optimisation of the appropriate therapy scheme for specific clinical cases/disease patterns that are controlled by long-term results. Also here was developed and optimized the treatment strategy and treatment algorithm for optimizing the diagnosis, the treatment and control of operative and postoperative treatment. The short- and long-term results of these optimized therapy were planned documented and evaluated in the regular intervals.

Ultimately, this presentation is going to show the specifics of the method, the surgical technique, problematic, results as well as the effectiveness of the method, determining the limits of indication and the modernization of the method based on the clinical study of 274 patients (895 vertebral bodies) with tumours/metastases at the spine.

2. PATIENTS/MATERIAL AND METHODS

This study concerned male and female patients affected by spinal tumours (large symptomatically hemangiomas) and spinal metastases with destructions/osteolysis as well as fractures with dangers of instability (proven through X-ray, CT/MRI, F18-FDG whole body PET, whole body bone Scintigraphy) and with a pain syndrome.

Preoperatively every patient underwent following diagnostic, including tumour staging: clinical (including pain intensity-documentation by VAS), radiological (X-Ray in 2 layers, CT, MRI [obligatory], whole body scintigraphy or Positron-Emission Tomography with F18-FDG *etc.*), histopathological (if possible preoperatively, especially at the known primary tumour otherwise intraoperatively for every patient), where the diagnosis of the tumour or metastases of the spine was saved both clinically and radiologically as well as histologically for every patient.

There is a pro- and retrospective clinical study, in which case some additional important innovations were introduced to the well-known "classic" Cavity/Coblation method: additional performing of the kyphoplasty for fracture reduction, extraction or removal of the tumor remains from the vertebral body immediately after cavity/Coblation under pressure, immediate local radiotherapy or irradiation, timely implementation of physiotherapy. Also here was developed and optimized the treatment strategy and treatment algorithm for optimizing the diagnosis, the treatment and control of oper-

ative and postoperative therapy. The short- and long-term results of these optimized therapy were planned documented and evaluated in the regular intervals.

The Cavity/Coblation method is approved for the treatment both in Germany, USA and in other several countries. All patients were informed in accordance with standard length about the treatment methodology, treatment strategies, study course or therapy control intervals, data protection, possible complications *etc.*

2.1 Description of Cavity/Coblation-method

The Cavity Spine Wand/Probe (see Figure 1) creates a free space in the vertebral body (cavity with the destruction of the tumor tissue through the creation of the plasma field (Coblation = controlled Ablation) at low temperature (approx. 42°C), through plasma emitted High-frequency energy. Through the removal of tumour tissue not only is a cavity for filling with cement created but the complete destruction/evaporation of tumour cells can be achieved. The tumour cells are destroyed/evaporated as a result of the application of the plasma field to molecular bridges which breaks up tumour tissue, leading to the denaturation of the molecule and consequently to a sublimation of the molecule to a gaseous state. The resulting benefits are considerable: through the creation of room and the simultaneous coagulation and removal of the tumour (local approx. 42°C, cold energy) the cement can be inserted without pressure. The risks of extravasation, as well as tumour spread, are considerably minimised. Further operational risks, above all blood loss, complications and surgical times are considerably reduced.^[1, 17, 18, 29-31]

We have combined the method with balloon kyphoplasty^[21-23] with custom-made extremely thin trocars to allow for Fracture reposition and Kyphosis reduction with the bone cement application for vertebra stabilisation and for filling the defect. The plasma probe is pre-bent and can be rotated meaning the ablation was done in multiple directions under permanent control using X-ray in 2 projections during the surgery.

2.2 OP-technique Cavity/Coblation

The operation is performed in prone position. The entrance to one or multiple concerned vertebral bodies is created percutaneously trans- or extrapedicularly. An X-ray control, taken in 2 levels, is constantly performed during the entire operation.

Step 1: Inserting the custom cannula with a thread to get a better and a more stabilised grip. Extracting of biopsy material for microbiology and histopathology through a specialised biopsy cannula (see Figure 2).

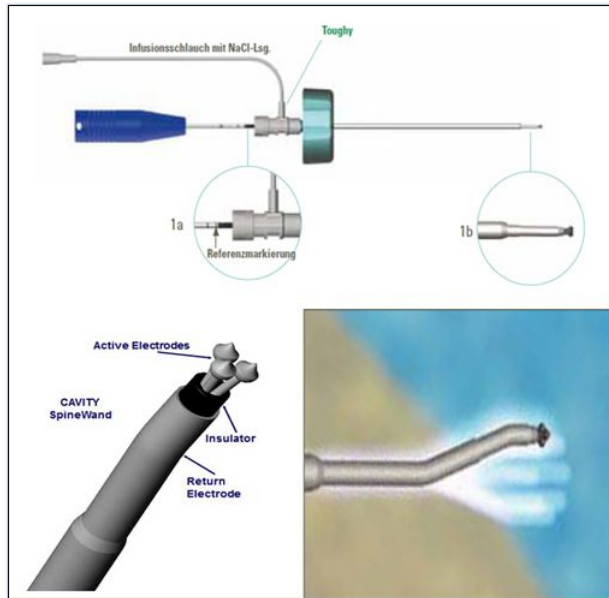


Figure 1. Cavity unit: Cavity access trocar with attached Cavity Spine Wand/ probe and infision line with the electrolyte NaCl

The bent tip of the Cavity Spine Wandes leaves the tumor ablation perform in several directions. CAVITY™ SpineWand: has activated multiple active electrodes in order to create the plasma field, the ablation only happens in the forward motion, electrolyte solutions and slats such as NaCl are required to create the plasma field, the sonde is bent forward to create more room.

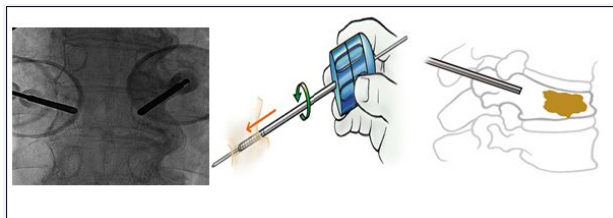


Figure 2. Cavity tumour: OP-Step 1

Inserting the special thin entry cannula/trocars with the thread (in order to have a better and more stable grip: transpedicularly or extra pedicularly).

Step 2: Work with the Cavity Spine Wand in many directions, removal of the tumour with minimal blood loss because the blood vessels coagulate through plasma energy, creating a space devoid of tumour (see Figure 3).

Note: at the low temperature of 42°C are usually happened no injury and necrosis of the bone tissue in the vertebral body. In this case only the tumor tissue is removed. Even with the application of the bone cement, before it is hard to imagine the local temperatures above 70°C, which does not hurt the bone tissue developed, but vice versa - improves the composition between the bone cement and the bone tissue.

In laser ablation, for example, yet developed much higher local temperatures - over 500°C-600°C, which of course is the injury-Danger for the surrounding structures much larger. The plasma field can theoretically occurred intraoperatively as injuries to nerves, blood vessels and internal organs. In order to avoid this, the X-ray control in 2 planes: frontal and sagittal of the probe position is continuously carried out during the entire operation. In our study however not passed such violations.

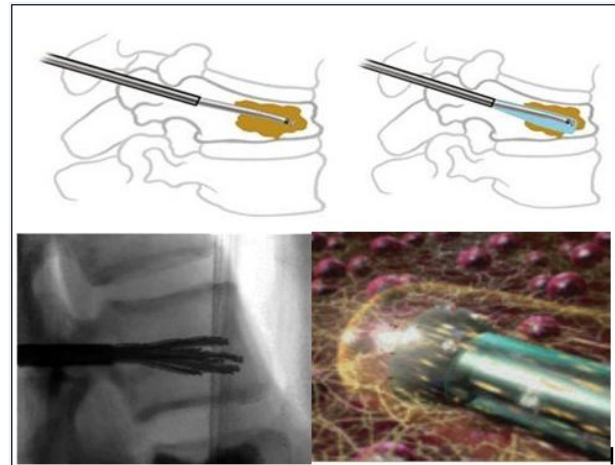


Figure 3. Cavity tumour: OP-Step 2

Working with the CAVITY Spine Wand, removal of tumour; creating free room. Inserting the cement (prior to that the rests of the tumour and the NaCl-solution is vacuumed through pressure through the cannula). Coblation effect: the Cavity Spine Wand moves and works only in forward direction. With a plasma field induced tumor cells are decomposed into gaseous components. The clinical trials show the effectiveness of the CAVITY™ Spine Wand TM: 2.5-3.5 qcm of tumour can be removed – Cavity.

Step 3: Insertion of the bone cement through pressure of the vacuum after the remainder of the tumour and the NaCl 0.9% solution have been removed through the cannula. Kyphoplasty allows for the expansion of room in the vertebral body as well as fracture reposition in the case of fracturing (see Figure 4).

Explanation: In the same surgical session can be effectively treated only one, or two or more vertebrae by Cavity/Coblation. For Cavity/Coblation was used always as electrolyte the NaCl 0.9% solution (physiological solution). After the removal of the tumor tissue by Coblation was the remains of the NaCl 0.9% with tumor residues removed and sucked away from the vertebral body. After this was performed the baloon kyphoplasty using the PMMA (Polymethylmethacrylat) bone cement, which is always used in kyphoplasty.

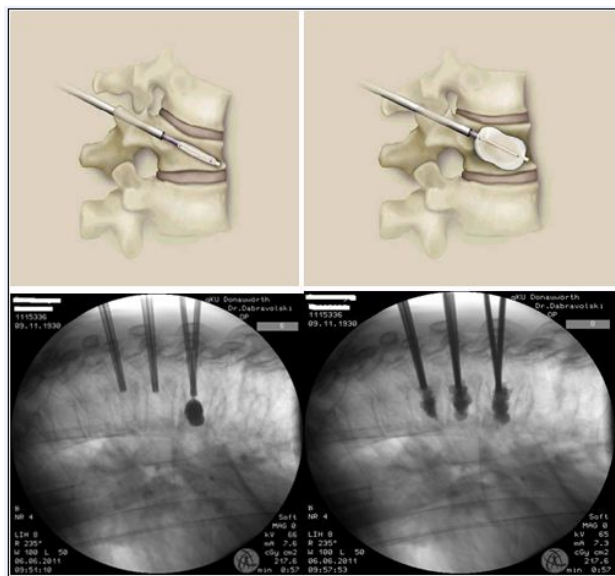


Figure 4. Cavity tumour: OP-Step 3
 The fracture reposition occurs, if necessary, prior to the balloon kyphoplasty. Then the stabilization of the vertebral body is carried by the bone cement.

2.3 Postoperative therapy controls

Postoperative results were controlled clinically and radiologically at regular time intervals (after 2, 14 days, after 3, 6, 12, 24, 36, 48 months), including questionnaires concerning the intensity of pain after VAS, the inhibition or improvement of life quality, the survival rate, etc. Particular attention was paid to tumour staging in order to exclude a local relapse or further metastasis.

3. RESULTS

3.1 Treated patients and metastases species

Within 6 years (03/08-04/14) more than 274 patients (171 female, 103 male, age range of 31-92 y. old average age of 65.7 y.) or 895 vertebral bodies with tumours or metastases were treated (see Table 1).

Table 2 shows the distribution of patients with tumours/metastases with osteolysis/bone destruction and with/without pathological vertebral fractures. During one operative session either only one or two and several (up to 8) affected vertebrae were treated by the Cavity/Coblation in different patients.

3.2 Operated vertebrae

Total 42 vertebral bodies or 4.69% of all spine tumours/metastases were treated at the cervical spine, 510 vertebral bodies or 56.98% at the thoracic spine and 343 vertebral bodies or 38.32% at the lumbar spine (see Figures 5 and 6). 12 patients were treated 3 times (at different vertebral bodies), 23 patients - 2 times (at different vertebral bodies)

and 240 patients - 1 time at single or multiple vertebral bodies.

Table 1. Treated tumours and metastases of the spine

Tumours/Metastases	N (Number of patients)	% (of all clinical cases)
Tumours		
Hemangioma (large, symptomatic, with therapy-resistant pain syndrome)	24	8.76%
Metastases from		
Breast cancer (Mamma-Ca.)	54	19.7%
Plasmocytoma	44	16.06%
Lung/Bronchial cancer (Lung-Ca.)	37	13.5%
Renal carcinoma (Kidney-Ca.)	28	10.22%
Uterine/Ovarian cancer (Uterine-Ca.)	25	9.12%
Thyroid cancer (Thyroid-Ca.)	20	7.3%
Bladder/Prostate cancer (Prostate-Ca.)	17	6.2%
Pancreatic cancer (Pancreatic-Ca.)	11	4.01%
Gastrointestinal cancer (Gastrointestinal-Ca.)	10	3.65%
Malignant melanoma (Skin cancer)	4	1.46%
Total	274	100%

Table 2. Vertebrae/Segments, who were treated in one surgical session by Cavity/Coblation

Level/Vertebrae	Total number of vertebrae/%	Number of patients/%
1 vertebra	29/3.24%	29 patients/10.59%
2 vertebrae	122/13.63%	61 patients/22.62%
3 vertebrae	213/23.8%	71 patients/25.91%
4 vertebrae	240/26.82%	60 patients/21.9%
5 vertebrae	170/18.99%	34 patients/12.41%
6 vertebrae	84/9.39%	14 patients/5.11%
7 vertebrae	21/2.35%	3 patients/1.09%
8 vertebrae	16/1.79%	2 patients/0.73%
Total vertebrae:	895/100%	Total patients: 274/100%

It was taken the following distribution of patients into treatment groups according to the surgical procedures:

Group 1: for 191 patients –only Cavity/Coblation with vertebroplasty/balloon kyphoplasty, percutaneously (see Figures 7-10) was performed.

Group 2: for 22 patients - the Cavity/Coblation with additional microsurgical decompression and hemi- respectively laminectomy (in mini-open technique), tumourectomy and primary stabilisation by the balloon kyphoplasty, all cases in the thoracic spine area(see Figures 11 and 12).

Group 3: for 61 patients, the Cavity/Coblation with additional dorsal percutaneous instrumentation with internal fixture over several segments (3 up to 8) was performed, to allow for stabilisation and possibly straightening/correcting (especially for fractures with kyphosis and with stenosis). Done after the decompression and laminectomy, to avoid the sintering and further secondary deformations).

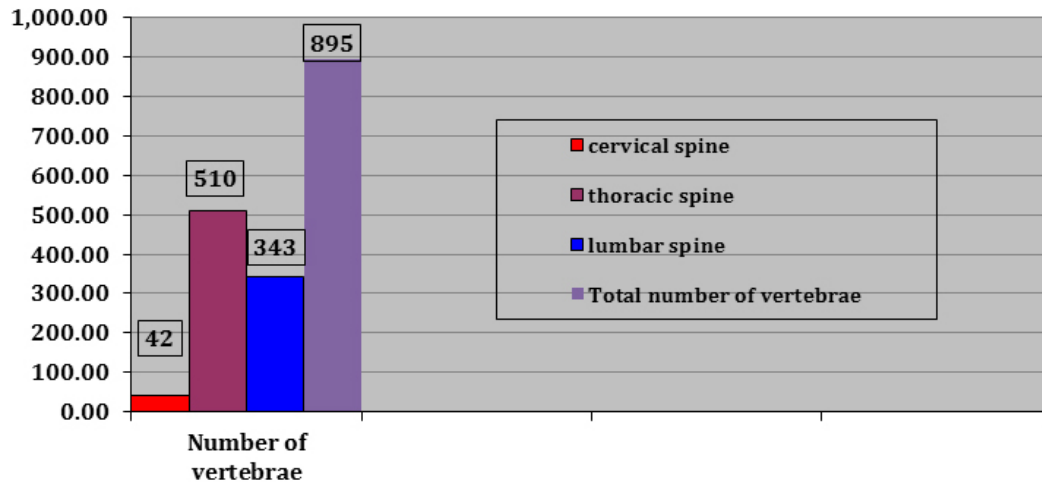


Figure 5. Distribution of the treated vertebrae according to the sections of the spine

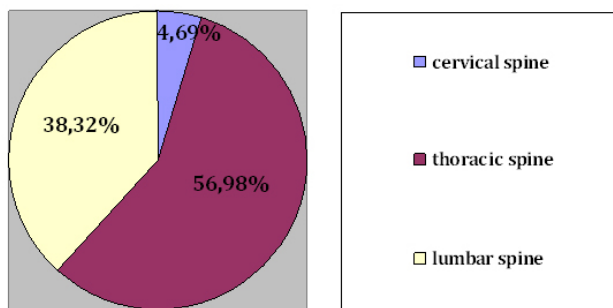


Figure 6. Percentage of the treated vertebral body in comparison to the spread in the spine segments

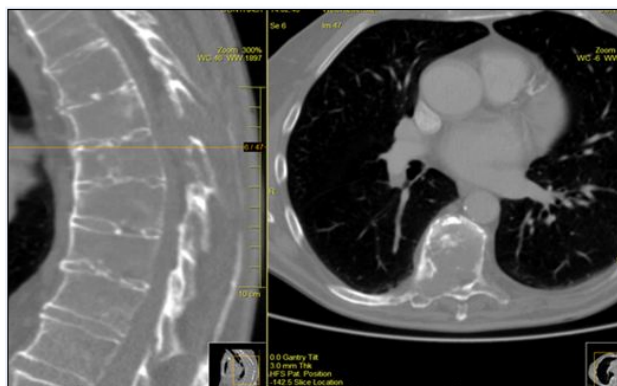

Figure 7. CT preoperatively, multiple osteolytic metastases of prostate cancer in the thoracic spine in Th6-10
Transversal layer from TH9: massive defect in the vertebral body and posterior lamina, right accented with spinal cord compression (see also Figures 11 and 12: clinical case 2).

For the 2 and 3, treatment cases/groups the Cavity/Coblation was combined with microsurgical decompression and tumour removal. The blood loss through the previous Coblation with coagulation and removal of tumour tissue was considerably

less than for just the decompression and tumour removal (without cavity) (see Table 3). The dorsal instrumentation was performed minimal invasive percutaneously as well as very precisely through the usage of X-Ray-imager. It was controlled two times respectively using 3D navigation to place the screws precisely, which is especially important in cases of metastasis in the neighbouring vertebral bodies.

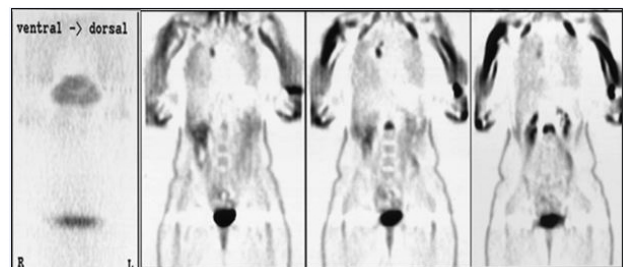


Figure 8. Full body positron emission tomography with F18 - FDG preoperatively at a 46-year-old female patient with suspected metastases in the skeleton and other organs of an unknown tumor
One sees here focal pathological tracer more enrichment: 1) focused on the area of 1 lumbar vertebra; 2) 1 large stove in re. upper lobe, located hilusnah and 1 additional point-like oven immediately cranial thereof. The PET diagnosis of adenocarcinoma (bronchial carcinoma) with metastasis to the skeleton (in the lumbar vertebrae 1) was later confirmed by other methods (especially by histology).

The results were controlled both clinically and radiologically 2, 14 days, 3, 6, 12, 24, 36, 48 and 60 months after the operation. Postoperatively no sintering or Fixture-Loosening/Dislocation appeared. In all 3 control groups the results, especially for the local tumour relapse and the survival rate, was dependent exclusively on the number of metastases and extent of their spread and not on the operative

method (for example additional percutaneous instrumentation).

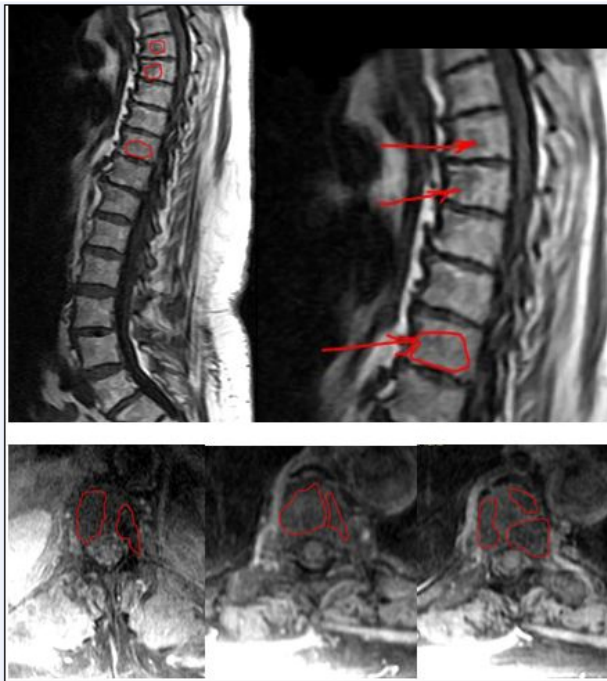


Figure 9. Clinical case No. 1
 Patient W., female, 78 years old, multiple metastases of ovarian cancer in the thoracic spine: osteolysis in large T6, T7, T10, massive progressive pain syndrome (VAS 8-9). MRI preoperatively: large osteolysis T6, T7, T10: sagittal and transverse slices.

3.3 Pain syndrom reduction after the operation

The pain was reduced dramatically and resulted in high patient satisfaction and rapid life quality improvement of all patients. Preoperative pain related to the spinal tumours/metastases was determined through the visual analogous scale (VAS), differentiated for back pain, as well as pain in the arms and legs in the case of the spinal canal stenosis. Postoperatively, the pain was on average 6-8 VAS points lower, going from 7-10 point preoperatively to 0-3 point postoperatively.

3.4 Biopsy

All patients had samples (biopsies) taken intraoperatively from the affected/treated vertebral body, in order to be able to perform microbiological (MiBi, for exclusion of infections/spondylitis) and histopathological (histology, determination of tumour/metastasis type/source and primary tumour determination, tumour grading respectively) tests.

In 63 (22.6%) cases diagnostics and operation were able to discover, define precisely and treat previously undiscovered primary tumours and metastases.

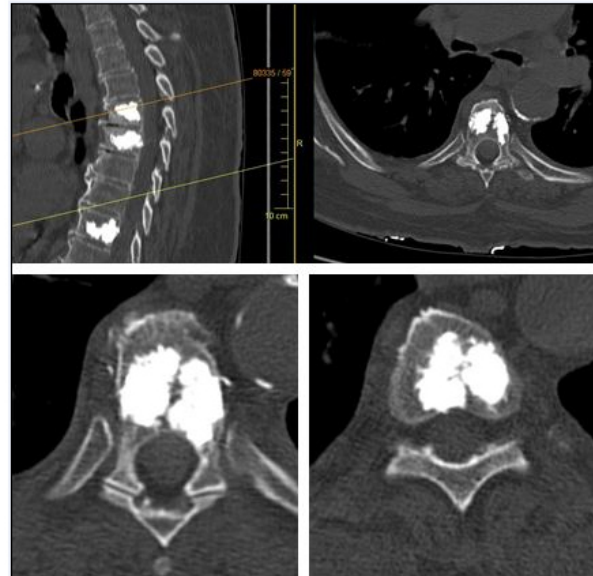


Figure 10. Clinical case No. 1
 Patient W., female, 78 years old, multiple metastases of ovarian cancer in the thoracic spine: osteolysis in large T6, T7, T10. CT control 1 year postoperatively after the Cavity / Coblation: sagittal and transversal slices from T6, T7, T10, chemotherapy and radiotherapy on the thoracic spine: no local recurrence, no material loosening. Pain relief after the surgery: from VAS 8-9 before the operation to VAS 1-2 postoperatively.

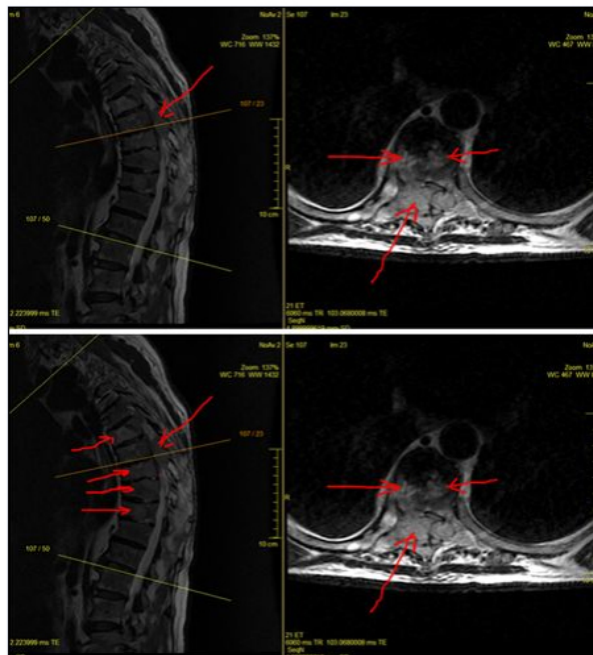


Figure 11. Clinical case No. 2
 Patient F., 82 years old, male, MRI preoperatively: metastases from prostate cancer in Th6-10 with osteolysis and with stenosis and spinal cord compression in Th7-8, with neurological deficits/incipient paraplegia syndrome, with massive progressive pain syndrome.

Table 3. Comparison of the therapy methods of tumours metastases of the spine: Cavity alone, Cavity with decompression, Cavity with decompression and dorsal stabilisation and with conventional open tumour surgery including vertebral body replacement and dorsal.^[6-10]

Kind of operations	Number of operations	Blood loss (depending on the number of levels and kind tumor)	Duration of the operation (depending on the number of levels and kind tumor)
Only Cavity with Vertebroplasty/Kyphoplasty	172	about 5-20 ml	about 30-60 min
Cavity with mini open microsurgical decompression	19	about 20-100 ml	about 40-80 min
Cavity open with mini open decompression and percutaneous stabilization	59	about 30-130 ml	about 60-120 min
Decompression, tumourectomy, vertebral body replacement and posterior stabilization (for comparison)	for comparison	about 1,500-3,500 and > ml	about 180-450 and > min

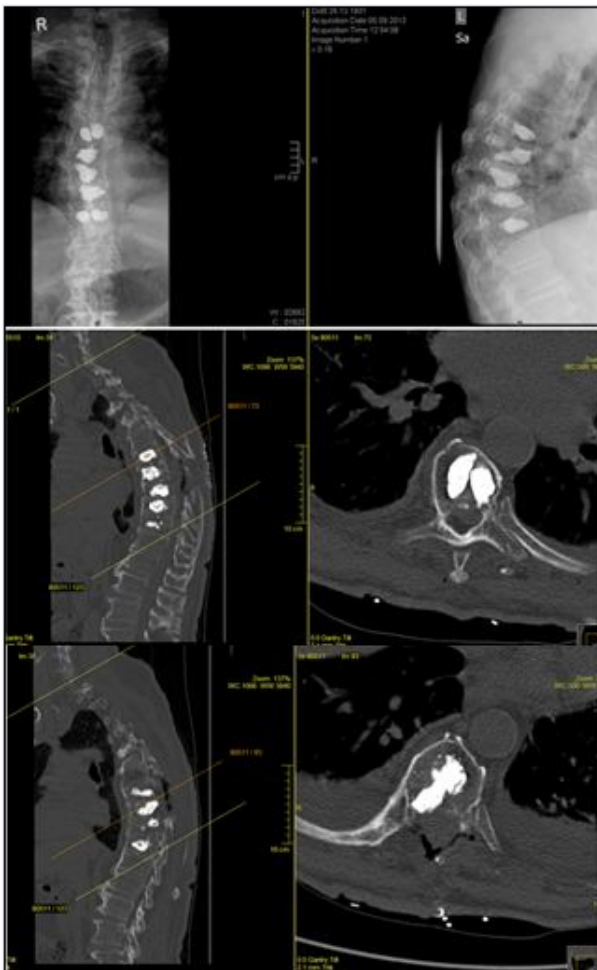


Figure 12. Clinical case No. 2

Postoperatively X-Ray and CT. Surgical treatment: Cavity/Coblation T6-T10 with minimally invasive decompression and laminectomy microsurgical in Th7-8. Instant significant pain relief after surgery (VAS 9-10 up on VAS 2-3), stability improvements, immediate mobilization directly after surgery was possible. Postoperatively: resection of the prostate, radiotherapy BWS, chemotherapy.

All patients were able to be mobilised rapidly after the operation, the blood loss was minimal and further treatment was

usually initiated immediately.

The risk of hemangiomas of one or more segments with massive bleeding tendencies and risk of cement embolism was particularly decreased after the ablation and the coagulation of the tumour vessels through the plasma field.

Also for the treatment of plasmocytomas, in particular of large osteolysis and fractures, Cavity/Coblation followed by kyphoplasty showed very good results.

3.5 Complications

In 39 cases, where large vertebral damage was present, small cement leakage laterally or in the intervertebral disc space were detected without clinical relevance.

194 patients (105 women, 89 men) have died as a result of tumour manifestations of the metastasis in the internal organs.

Nevertheless, the length of survival was increased independently of the type of tumour through the application of Cavity/Coblation with Radiation and chemotherapy. The pain syndrome was significantly decreased and the life quality was significantly better compared to average results of palliative therapy without metastases-/tumour resection through Cavity/Coblation.^[6-9] Table 4 shows the result of actual survival rates and survival time after Cavity/Coblation of all hemangiomas and all metastases types in the study and comparison the average survival rates for each tumor-/metastasis type (according to the literature, depending on the tumor type, metastasis size, metastasis number and spread).

3.6 Local recurrence control postoperatively

Especially important was the control of the local findings to prevent the tumour recurrence at the treated vertebral bodies. In Table 5 the data concerning the therapy controls or rather the metastases-/local relapse controls are displayed.

Table 5 shows that local relapse occurred in 12 of 54 cases or 22.3% of metastases of the mamma carcinoma; in 1 of 44 Cases or 2.3% of metastases of plasmocytoma, in 3 of 37

cases or 8.1% of metastases of lung carcinoma, in 7 of 28 cases or 25.0% of metastases of renal carcinoma, in 2 of 25 cases or 8.0% of metastases of uterine-/ovarian cancer, in 5 of 20 cases or 25% of metastases of the thyroid cancer, in 3 of 17 cases or 17.6% of metastases of the bladder-/prostate cancer and in 2 of 11 cases or 18.2% of metastases of pancreatic cancer. Altogether it concerns 35 of 250 cases with

metastases or only 14.0% (another 24 were patients with hemangiomas – here are no local recurrence) of local relapse in 1 or 2 areas/vertebral bodies of extensive metastases of very aggressive, lowly differentiate tumours that only appeared 1 or 2 years after. The first 3 and 6 months usually passed without any local relapse. The local relapses were treated by locally aimed radiation therapy as well as chemotherapy.

Table 4. Average survival rate/-times after Cavity/Coblation for every tumour/metastases during the study and comparison the average survival rates for each tumor-/metastasis type (according to the literature, depending on the tumor type, metastasis size, metastasis number and spread.)

Tumour/Metastases	Number/ %	Survival rate/times average for each type of tumor after Cavity/Coblation: Number of survivors/total tumours/%					Average survival time for each type of tumor (in years)
		1 year	2 years	3 years	4 years	5 years	
<i>Tumours</i>							
Hemangioma	24/100%	24/100%	24/100%	24/100%	24/100%	24/100%	> 5 years
Overall survival for hemangiomas	24/100%	24/24/100%	24/24/100%	24/24/100%	24/24/100%	24/24/100%	
<i>Metastases from</i>							
Breast cancer (Mamma-Ca.)	54/100%	45/54/83.3%	26/54/48.1%	11/54/20.4%	1/54/1.9%	0/54/0%	0.5-2.5 years
Plasmocytoma	44/100%	44/44/100%	43/44/97.7%	42/44/95.5%	41/44/93.2%	38/44/86.4%	2-5 and > years
Lung/Bronchial cancer (Lung-Ca.)	37/100%	9/37/24.3%	3/37/8.1%	0/37/0%	0/37/0%	0/37/0%	0.2-1.5 years
Renal carcinoma (Kidney-Ca.)	28/100%	15/28/53.6%	6/28/21.4%	0/28/0%	0/28/0%	0/28/0%	0.2-2.0 years
Uterine/Ovarian cancer (Uterine-Ca.)	25/100%	12/25/48.0%	5/25/20%	1/25/4.0%	0/25/0%	0/25/0%	0.3-2.0 years
Thyroid cancer (Thyroid-Ca.)	20/100%	12/20/60.0%	6/20/30.0%	2/20/10.0%	0/20/0%	0/20/0%	0.3-2.0 years
Bladder/Prostate cancer (Prostate-Ca.)	17/100%	15/17/88.2%	8/17/47.1%	3/17/17.6%	0/17/0%	0/17/0%	0.5-2.5 years
Pancreatic cancer (Pancreatic-Ca.)	11/100%	7/11/63.6%	2/11/18.1%	0/11/0%	0/11/0%	0/11/0%	0.3-1.5 years
Gastrointestinal cancer (Gastrointestinal-Ca.)	10/100%	7/10/70.0%	3/10/30%	0/10/0%	0/10/0%	0/10/0%	0.4-1.5 years
Malignant melanoma (Skin cancer)	4/100%	2/4/50%	1/4/25%	0/4/0%	0/4/0%	0/4/0%	0.5-1.3 years
Overall survival rate for all patients with spinal metastases in the study over a period of 5 years	250/100%	168/250/67.2%	103/250/41.2%	59/250/23.6%	42/250/16.8%	38/250/15.2%	only about 10%-20% of all patients with spinal metastases are still alive after 2 years an average

4. DISCUSSION AND CONCLUSION

When treating patients with tumours and metastases of the spine, it is vitally important not only to find the primary tumour and treat it but also to find and treat all possible metastases both loco-regionally as well as distant metastases. In many cases of radically extensive operative therapy, a metal

fixture of titanium is used which, due to its size, creates many large artefacts that negatively impact image quality of computer tomography and especially of MRI. The implants of steel are furthermore a contraindication for the execution of the most important diagnostic tool for the local tumour search: the MRI and with the local relapse diagnostic.^[6-9,37]

Here, and in many other cases, the F-18-full body-Positrons-Emissions-Tomography (F18-FDG-GK-PET) offers a successful replacement for patients with metastases of the spine, which was also used effectively in our study for the primary tumour staging, as well as for the relapse-control (see

Figure 8). For the treatment of tumours/metastases of the spine F-18-FDG-PET additionally offers a very valuable examination method to detect and localise metastases at the spine, in the skeletal system as well as the lymph nodes, lungs brain, liver and other organs and tissues.

Table 5. Postoperative results for all tumours/metastases for local control/recurrence exclusion after Cavity/Coblation followed by local radiation therapy (max. radiation dose 30-40 Grey) and chemotherapy of metastases

Tumour/Metastases	Number/ %	Control local tumor recurrence rate N local tumor recurrence/% for each type of tumor								
		¼ year	1/2 year	1 year	2 years	3 years	4 years	5 years	N/%	
<i>Tumours</i>										
Hemangioma	24/100%	0%	0%	0%	0%	0%	0%	0%	0%	0%
Total local recurrence		0%								
<i>Metastases from</i>										
Breast cancer (Mamma-Ca.)	54/100%	0/54/0%	0/54/0%	2/54/ 3.7%	3/54/ 5.6%	7/54/ 13%	----	----		12/54/ 22.3%
Plasmocytoma	44/100%	0/44/0%	0/44/0%	0/44/0%	0/44/0%	0/44/0%	0/44/0%	1/44/2.3%		1/44/2.3%
Lung/Bronchial cancer (Lung-Ca.)	37/100%	0/37/0%	0/37/0%	0/37/0%	3/37/ 8.1%	-----	-----	-----		3/37/8.1%
Renal carcinoma (Kidney-Ca.)	28/100%	0/28/0%	1/28/ 3.6%	3/28/ 10.7%	3/28/ 10.7%	-----	-----	-----		7/28/ 25.0%
Uterine/Ovarian cancer (Uterine-Ca.)	25/100%	0/25/0%	2/25/ 8.0%	0/25/0%	0/25/0%	0/25/0%	-----	-----		2/25/8.0%
Thyroid cancer (Thyroid-Ca.)	20/100%	0/20/0%	1/20/ 5.0%	1/20/ 5.0%	2/20/ 10.0%	1/20/5%	-----	-----		5/20/25%
Bladder/Prostate cancer (Prostate-Ca.)	17/100%	0/17/0%	0/17/0%	1/17/ 5.9%	1/17/ 5.9%	1/17/ 5.9%	-----	-----		3/17/ 17.6%
Pancreatic cancer (Pancreatic-Ca.)	11/100%	0/11/0%	0/11/0%	1/11/ 9.0%	1/11/ 9.0%	-----	-----	-----		2/11/ 18.2%
Gastrointestinal cancer (Gastrointestinal-Ca.)	10/100%	0/10/0%	0/10/0%	0/10/0%	0/10/0%	-----	-----	-----		0/10/0%
Malignant melanoma (Skin cancer)	4/100%	0/4/0%	0/4/0%	0/4/0%	0/4/0%	-----	-----	-----		0/4/0%
Total local recurrence rate for all patients with spine metastases in the study over a period of 5 years	35/250/14.0%									

Note. Examination methods by the follow up: X-Ray, Computer tomography (CT), MRI, if needed (especially after instrumentations with existing implants with F18-FDG-PET or a whole body skeletal scintigraphy. (----) – no Survival rate/no surviving patients with the respective tumour/metastases at this time.

Other known traditional treatment methods show considerable disadvantages or side effects. Cryotherapy, for example, performed at very low temperatures, is very labour intensive, a complete metastases removal is predominantly impossible and there is a substantial risk of damaging healthy tissue.^[1,2] Laser therapy occurs at higher temperatures locally with 500°C-600°C. Amongst other dangers, it risks damaging healthy tissue.^[2,4] The radiohighfrequency method^[2,3,5,6,9] for example, with the Rita Starburst™ MRI device, works with radiohighfrequency and also generates a high temperature (more than 400°C) to destroy tumour cells. However, a complete destruction of the tumour/metastases is barely possible and healthy tissue including vessels and nerves are at risk. The for several years known method kyphoplasty

in combination with the intraoperative radiotherapy is according to the first results and publications promising but is very complicated, expensive, can be performed only in large centers with special equipment for radiotherapy.^[38]

The percutaneous Cavity-Coblation-method offers patients with tumours/metastases of the spine of higher OP-risk a relatively safe, minimally invasive and minimally traumatic procedure, which is confirmed by short-term as well as long-term results. Through the percutaneous minimal invasive access, the operative risk, in particular, blood loss, as well as surgical times, were reduced. Other important qualities are the rapid post-operative pain reduction and stability.^[2,3,6,10,16-18]

So far, clinical studies on Cavity/Coblation have been carried out and published especially in the United States, Japan and France with relatively small sample size whereby multiple authors have confirmed the effectiveness of the method.^[13-19]

In this study the already known “classic” Cavity/Coblation method has been modernised and completed:^[6]

- (1) Through the combination of Cavity/Coblation with balloon kyphoplasty^[21-23] with special super thin balloons/trocar, fracture repositioning and Kyphosis correction in one or multiple segments, also at the thoracic and at the cervical spine remains possible.
- (2) After the destruction of the tumour or after the Cavity/Coblation, the remains of the tumour are removed through pressurised vacuum that decreases the relapse danger considerably.
- (3) The Cavity/Coblation method in the sample patient group was combined postoperatively with local radiation as well as chemotherapy. Particularly important is an obligatory treatment (surgery, radiation, chemotherapy) of the primary tumour and of all metastases. Because Cavity does not create large wounds (even when multiple segments are being targeted) the radiation could begin practically immediately or few days after the operation. In comparison, extensive operations create large wounds that allow radiation and chemotherapy only after many weeks due to the high risk of wound healing disturbance.^[6-9,31,37] The low intraoperative temperatures (only approximately 42°C, with plasma - cold energy) mean the healthy structures/organs/bones are not damaged, which considerably improves the reparatory process in lesion areas.
- (4) Cavity/Coblation was combined in our clinical study in cases of spinal stenosis with the microsurgical decompression that resulted in minimised blood loss.

An interdisciplinary setting or cooperation of spinal surgery with other disciplines – with radiotherapy, oncology, radiology, and pathology is of utmost importance. It is not uncommon that, for the affected patients, the primary tumour is unknown and through diagnostics, according to oncological-chirurgical guidelines at multiple localisations, a biopsy has to be carried out in order to start a targeted, suitable tumour therapy.^[6-9,31,37]

4.1 Problematic/Particularities

The treatment of tumours and metastases of the spine are a challenge. Of utmost importance is the interdisciplinary collaboration. Depending on bone stability, compression of the neural structures, radiosensitivity of the tumour tissue, the

pain symptomatic and, last but not least, the overall prognosis, an individually adjusted therapy of the spine metastases has to be planned.^[6-9,11,12,37]

The proper indication and choice of the appropriate treatment method are crucial for the treatment of the metastases of the spine. The right therapy has to always be determined on a case by case basis, depending on certain criteria and parameters (clinical, radiological, histopathological, *etc.*). The known Score-Systems (Tokuhashi-Score, Karnofsky-Index, Tomita-Score, *etc.*) are helpful in deciding which method and to what extent (palliative or rather radical chirurgical tumour resection, *etc.*) is best suited for every individual case. Since it is a palliative method in a variety of patients, for example for multimorbid patients, especially with multilocular tumour manifestations/metastases in the skeleton units or vertebral body, while likely to seek a comprehensive surgical complete resection often therapeutic approach is required for solitary metastases. These different Score-Systems, which are used to determine the treatment prognosis and survival prognosis, have limited diagnostic significance and can only be used as pointers.^[7-9,11,12,37]

In many cases, it is not possible to remove the tumour tissue completely which explains why directly after operation a post-operative radiation has to be carried out. An exclusively local radiation (in general maximum total dose of 30-40 Grey) without previous operative removal of the tumour tissue does not completely remove the tumour, in particular for large osteolysis in several vertebrae with a circumference of more than 2 cm-3 cm. The local radiation dose has to be increased considerably, which can cause damage to skin, subcutaneous tissue, muscle tissue as well as blood vessels and nerves.^[9,32-34,36]

For multi morbid oncological patients with poor prognosis, in particular with large osteolysis or pathological fractures in the spinal area and with a massive drug-resistant pain syndrom of the spine for whom until recently no adequate therapy (especially surgical) was available and who, due to practical immobility, died rapidly of various comorbidity (pneumonia, embolism, heart- and circulatory failure, depression), Cavity/Coblation offers an opportunity to attain a certain degree of mobility including capacity und ability to walk. This, as well as the resultant reduced pain symptoms, improves the quality of life noticeably. What is most important - now can these critically ill patients spend those remaining time - the last days, weeks and months active, pain-free and fully mobile home with her family and not in the hospital.

Like any other method Coblation/Cavity has its limits and indication restrictions. Those are in particular large exten-

sive Metastases with destruction of one or multiple vertebral bodies. For optimum metastases treatment, it is necessary that within the vertebral body with a tumour metastasis, all 6 or at least 4 vertebral walls for the optimum support of the bone cement still exist.

Additionally, the method has a steep learning curve. The extent of the operation and the indication have to be checked necessarily and adjusted very precisely and accurately for every patient and every case. Also important is a precise surgical technique, where the primary goal is a highly precise Metastases removal.

4.2 Practical conclusion

When treating patients with metastases of the spine following things have to always be considered: Proper Indications, patient choice, sober prognosis assessment.

- (1) Extensive preoperative Diagnostic: clinically, radiologically including tumour-staging if possible also histological.
- (2) The extent of the operation and Indication has to be planned, checked, and submitted very precisely for each patient individually.
- (3) Tight collaboration between the orthopaedists/spine surgeons with other specialists: with radiologists/nuclear physicians, radiotherapist, oncologists, histopathologists, pain therapists, physiotherapists,

etc.

- (4) A precise operative technique where the goal is a complete tumour tissue removal and stability.
- (5) Immediate postoperative execution of local radiation and chemotherapy, the primary tumour and other metastases always have to be treated as well.
- (6) Regular Check-Ups: clinically and radiologically (to exclude local relapse, loosening, fractures, evaluation of state, satisfaction, life quality, pain reduction, *etc.*).

The Cavity/Coblation method for the treatment of multiple metastases to the spine combined with kyphoplasty, chemotherapy and local radiation therapy immediately after surgery is a safe minimally invasive procedure, which has been with us evidenced by the short and long-term results. The effectiveness of the cavity method is confirmed by the numerous clinical studies and examples from other colleagues. The surgical risks of blood loss and surgical times are significantly lower and shorter, the complications rates are minimally. It is always important to consider an extensive diagnostic inclusive tumour staging, proper indication and Prognosis determination as well as precise surgical technique. In our opinion, the method shows much promise for the future.

CONFLICTS OF INTEREST DISCLOSURE

The authors declare no conflicts of interest.

REFERENCES

- [1] Callstrom MR, Atwell TD, Charboneau JW, *et al.* Painful metastases involving bone: percutaneous image-guided cryoablation-prospective trial interim analysis. *Radiology*. 2006; 241: 572-580. PMID: 17057075. <http://dx.doi.org/10.1148/radiol.2412051247>
- [2] Gangi A, Buy X. Percutaneous Bone Tumor Management. *Semin Intervent Radiol*. 2010; 27(2): 124-136. PMID: 21629402. <http://dx.doi.org/10.1055/s-0030-1253511>
- [3] Gangi A, Basile A, *et al.* Radiofrequency and laser ablation of spinal lesions. *Semin Ultrasound CT MR*. 2005; 26: 89-97. PMID: 15856810. <http://dx.doi.org/10.1053/j.sult.2005.02.005>
- [4] Woloszko J, Stalder KR, Brown IG. Lasers in Surgery: advanced Characterization, Therapeutics and Systems. *Spine*. 2000; 3907: 306-316.
- [5] Dupuy D, Hong R, Oliver B, *et al.* Radiofrequency ablation of spinal tumors: temperature distribution in the spinal canal. *AJR Am J Roentgenol*. 2000; 75: 1263-1266. PMID: 1044019. <http://dx.doi.org/10.2214/ajr.175.5.1751263>
- [6] Dabravolski D, Lahm A, Kasch R, *et al.* Chirurgische minimalinvasive Therapie der Tumoren und Metastasen an der Wirbelsäule durch Plasmafeld-Therapie (Cavity-Coblation-Methode) und Kyphoplastie mit und ohne zusätzliche dorsale perkutane minimalinvasive Instrumentation. Ergebnisse einer klinischen Studie über 218 Patienten. *Z. Orthop Unfall*. 2014; 152: 489-497. PMID: 25347550. <http://dx.doi.org/10.1055/s-0034-1382936>
- [7] Bartels RH, van der Linden YM, van der Graaf WT. Spinal extradural metastasis: review of current treatment options. *CA Cancer J Clin*. 2008; 58: 245-59. PMID: 18354080. <http://dx.doi.org/10.3322/CA.2007.0016>
- [8] Kreitz N. Operative treatment of bone metastases. *Medtropole*. 2009; 17: 647-650.
- [9] Delank K, Wendtner C, Eich H, *et al.* Treatment of spinal metastases. *Dt Arztebl*. 2011; 108(5): 71-80.
- [10] Suva LJ, Washam C, Nicholas RW, *et al.* Bone metastasis: mechanisms and therapeutic opportunities. *Nature Reviews Endocrinology*. 2011; 7: 208-218. PMID: 21200394. <http://dx.doi.org/10.1038/nrendo.2010.227>
- [11] Tokuhashi Y, Matsuzaki H, Toriyama S, *et al.* Scoring system for the preoperative evaluation of metastatic spine tumor prognosis. *Spine*. 1990; 15(11): 1110-1113. PMID: 1702559. <http://dx.doi.org/10.1097/00007632-199011010-00005>
- [12] Tomita K, Kawahara N, Kobayashi T, *et al.* Surgical strategy for spinal metastases. *Spine*. 2001; 26: 298-306. PMID: 11224867. <http://dx.doi.org/10.1097/00007632-200102010-00016>
- [13] Hall DJ, Littlefield PD. Radiofrequency ablation versus electrocautery in tonsillectomy. *J Otolaryngol Head Neck Surg*. 2001; 125(2): 211.

- [14] Bortnick DP. Coblation: an emerging technology and new technique for soft-tissue surgery. *Plast Reconstr Surg*. 2001; 107(2): 614-615. PMID: 11214084. <http://dx.doi.org/10.1097/00006534-200102000-00053>
- [15] Buy X, Basile A, Bierry G, *et al*. Saline-infused bipolar radiofrequency ablation of high-risk spinal and paraspinal neoplasms. *AJR Am J Roentgenol*. 2006; 186(5): 322-326. PMID: 16632695. <http://dx.doi.org/10.2214/AJR.05.0265>
- [16] Callstrom MR, Charboneau JW, Goetz MP, *et al*. Image-guided ablation of painful metastatic bone tumors: a new and effective approach to a difficult problem. *Skeletal Radiol*. 2006; 35: 1-15. PMID: 16205922. <http://dx.doi.org/10.1007/s00256-005-0003-2>
- [17] Do H, Rippey M, *et al*. Bone Ablation with a Plasma-mediated Radiofrequency-based Device: An in vivo Study of Temperature and Gross Effects in Tissue. Presented at Congress of Neurological Surgeons, Boston MA, Oct 2005.
- [18] Georgy BA, Wong W. Plasma-mediated radiofrequency-based ablation in conjunction with percutaneous cement injection for treating painful vertebral compression fractures resulting from metastasized malignancy. Presented at American Society of Spine Radiology, Las Vegas NV, Feb 2006.
- [19] Georgy BA, Wong W. Plasma-mediated radiofrequency ablation assisted percutaneous cement injection for treating advanced malignant vertebral compression fractures. *AJNR Am J Neuroradiol*. 2007; 28: 700-705. PMID: 17416824.
- [20] Mathis J, Wong W. Percutaneous Vertebroplasty: Technical Considerations. *J Vascular Interv References Radiol*. 2003; 14: 953-960. <http://dx.doi.org/10.1097/01.RVI.0000083255.29749.A8>
- [21] Dudeney S, Lieberman IH, Reinhardt MK, *et al*. Kyphoplasty in the treatment of osteolytic vertebral compression fractures as a result of multiple myeloma. *J Clin Oncol*. 2002; 20: 2382-2387. PMID: 11981012. <http://dx.doi.org/10.1200/JCO.2002.09.097>
- [22] Hentschel SJ, Burton AW, Fournery DR. Percutaneous vertebroplasty and kyphoplasty performed at a cancer center: refuting proposed contraindications. *J Neurosurg Spine*. 2005; 2: 436-440. PMID: 15871483. <http://dx.doi.org/10.3171/spi.2005.2.4.0436>
- [23] Nussbaum DA, Gailloud P, Murphy K. A review of complications associated with vertebroplasty and kyphoplasty as reported to the Food and Drug. *J Vasc Interv Radiol*. 2004; 15: 1185-1192. PMID: 15525736. <http://dx.doi.org/10.1097/01.RVI.0000144757.14780.E0>
- [24] Miko L, Szikora I, Grohs J, *et al*. Initial clinical Experience with radio-frequency based vertebral Augmentation in Treatment of vertebral compression Fractures. San Diego, CA: Annual Meeting of the Soc. of Interventional Radiology; 2009. <http://dx.doi.org/10.1016/j.jvir.2008.12.039>
- [25] Licht AW, Kramer W. Radiofrequency kyphoplasty: a new method for the treatment of osteoporotic vertebral compression fractures -a case study. *J Miner Stoffwechs*. 2010; 17(1): 35-37.
- [26] Elgeti F, Gebauer B. Radiofrequency kyphoplasty for treatment of osteoporotic and neoplastic vertebral fractures. *J Mineral Stoffwechs*. 2010; 17(1): 5-9.
- [27] Drees P, Kafchitsas K, Mattyasovszky S, *et al*. Radiofrequency Kyphoplasty - an innovative method for the treatment of osteoporotic vertebral compression fractures. *J Miner Stoffwechs*. 2010; 17(1): 15-19.
- [28] Reidy D. A biomechanical analysis of intravertebral pressures during vertebroplasty of cadaveric spines with and without simulated metastases. *Spine*. 2003; 28: 1534-1539. PMID: 12865840. <http://dx.doi.org/10.1097/01.BRS.0000076828.33308.5F>
- [29] Stadler KR, Woloszko J, Brown IG. Repetitive plasma discharges in saline solutions. *Physics Letters*. 2001; 79: 4503-4505.
- [30] Woloszko J, Stalder KR, Brown IG. Plasma characteristics of repetitively-pulsed electrical discharges in saline solutions used for surgical procedures. *IEEE transactions on plasma science*. 2002; 30: 1376-83. <http://dx.doi.org/10.1109/TPS.2002.801612>
- [31] Efremov NM, Adamiak BY, Blochin VI, *et al*. Experimental investigation of the action of pulsed electrical discharges in liquids on biological objects. *IEEE Trans Plasma Sci*. 2000; 28: 224-229. <http://dx.doi.org/10.1109/27.842908>
- [32] Lutz S, Berk L, Chang E, *et al*. Palliative radiotherapy for bone metastases: an ASTRO evidence-based guideline. *International Journal of Radiation Oncology, Biology, Physics*. 2011; 79: 965-76. PMID: 21277118. <http://dx.doi.org/10.1016/j.ijrobp.2010.11.026>
- [33] Moser T, Cohen-Solal J, Bréville P, *et al*. Pain assessment and interventional spine radiology. *J Radiol*. 2008; 89: 1901-1906. [http://dx.doi.org/10.1016/S0221-0363\(08\)74785-1](http://dx.doi.org/10.1016/S0221-0363(08)74785-1)
- [34] Roqué I. Radioisotopes for metastatic bone pain. *Cochrane Database of Systematic Reviews*. 2011; Iss. 7. <http://dx.doi.org/10.1002/14651858.CD003347.pub2>
- [35] Sze WM, Shelley M, Held I. Palliation of metastatic bone pain: single fraction versus multifraction radiotherapy. *Cochrane Database of Systematic Reviews*. 2002; Iss. 1. <http://dx.doi.org/10.1002/14651858.CD004721>
- [36] Guideline radionuclide: German Society of Nuclear Medicine. Radionuclide therapy for painful bone metastases 2007; Available from: www.awmf.org/uploads/tx_szleitlinien/031029_S1_Radionuklidtherapie_bei_schmerzhaften_Knochenmetastasen_11-2007_11-2012.pdf
- [37] Ulmar B, Huch K, Kocak T, *et al*. The prognostic influence of primary tumour and region of the affected spinal segment in 217 surgical patients with spinal metastases of different entities. *Z Orthop Ihre Grenzgeb*. 2007; 145(1): 31-8. PMID: 17345541. <http://dx.doi.org/10.1055/s-2007-960506>
- [38] Bludau T, Reis F, Schneider S, *et al*. Kyphoplastie kombiniert mit intraoperativer Radiotherapie (Kypho-IORT). *Der Radiologe*. 2015; 55(10): 859-867. PMID: 26420600. <http://dx.doi.org/10.1007/s00117-015-0018-1>