

CASE REPORTS

Clinical analysis of peritoneal mesothelioma

Ji Chen *, Hong Cui, Maolin Wang, Haoshu Niu

The Third Affiliated Hospital of Inner Mongolia Medical University, Hohhot, China

Received: June 25, 2012

Accepted: July 25, 2012

Online Published: October 15, 2014

DOI: 10.14725/dcc.v1n1p19

URL: <http://dx.doi.org/10.14725/dcc.v1n1p19>

Abstract

A case of Peritoneal mesothelioma (PM) in the Third Affiliated Hospital of Inner Mongolia Medical University was collected and analyzed on the basis of diagnosis, physical examination and treatment. Misdiagnosis of PM is very common since it is a rare disease. So this paper aims to enhance the doctors' awareness of peritoneal mesothelioma during clinical practice.

Key Words: Peritoneal mesothelioma, Clinical practise, Case discussion

1 Medical record

A 74-year-old woman who complained of abdominal distension of 2 months' duration was admitted to our hospital on July 28, 2011. The patient exhibited abdominal distension and fatigue of unknown origin, with no sign of abdominal pain or diarrhea, nausea or vomiting, haematemesis or melena, oliguria or edema, epistaxis or bleeding gums, xanthochromia, shiver or fever, palpitations, shortness of breath nor hematuria accompanied. She was not receiving any treatment when the symptom of abdominal distension progressed, urine volume decreased (specific amount unknown) without sign of edema two days prior to admission. She showed poor in spirit and appetite, with weight loss (body weight was not measured) since the occurrence of the disease, but no changes in bowel habits. She has history of (1) hypertension for 21 years which the highest intensity of blood pressure is 150/90 mmHg taking compound reserpine and hydrochlorothiazide tablets every other day to control. (2) psoriasis for 1 year and (3) hepatitis B for over 50 years. There was no reported history regarding tuberculosis, exposure to industrial poisons, trauma, blood transfusion or food

allergy consistent with the symptom. She was allergic to furaxone, and history of vaccination was not clear.

2 Physical examination

Data on the physical examination revealed her temperature 36.5°C, pulse rate 80/min, respiratory rate 18/min, blood pressure 110/80 mmHg. She was consciousness, with rosy lips, her skin and sclera without xanthochromia and no liver palms nor spider angiomas was found. A firm enlarged lymph node (5 cm × 5 cm) with poor activity could be touched on left groin, other superficial lymph nodes were not found to be enlarged. Double lung breath sounds resonance, and no abnormal breath sound was heard. The heart rate was 80 beats per minute, showing regularity in the force and rhythm of the heartbeat. Her bulging abdomen was soft, without gastrointestinal and peristaltic wave, gastric varices of abdominal wall, abdominal tenderness nor rebound tenderness and muscle tension. Nodes of varying sizes, firm quality, uneven surface, less smooth surface, poor activity, ill-defined margins without tenderness could be touched on

*Correspondence: Ji Chen, E-mail: nmgbgyyy@163.com; Address: Department of Gastroenterology, The Third Affiliated Hospital of Inner Mongolia Medical University, Hohhot, China

upper abdomen, periumbilical area and left abdomen. No enlargement of liver, spleen and kidneys beneath the rib was found, nor edema of lower limbs. Murphy's sign was negative, shifting dullness was positive, bowel sound was normal, without vessel murmur.

3 Laboratory examination

Blood test: WBC $7.16 \times 10^9/L$, GR 76.14%, PLT $347 \times 10^9/L$, Hb 121 g/L, RBC $4.23 \times 10^{12}/L$, HCT 37.6%, MCV 88.9 fl; Urine routine, stool routine and fecal occult blood test are normal, five items of hepatitis B, hepatitis C, syphilis, AIDS antibody are normal, biochemistry and liver function are normal. Ascites routine: Yellow muddy, rivalta test is positive, leukocytes $1,024 \times 10^6/L$, neutrophils 80%, Lymphocytes 20%; Ascites biochemistry: Glu 3.91 mmol/L, TP 56.5 g/L, Chloride 109 mmol/L; Normal thyroid function, CA125 773 U/ml, CA153 278 U/ml, CA199 normal, CA724 130.1 U/ml, CY211 26.5 ng/ml, NSE 25.7 ng/ml; PPD test is negative; Gastroscopy: Chronic superficial gastritis with erosion duodenitis. Colonoscopy: (1) Colitis (2) Mixed hemorrhoids. Pathology indicates: (colon) Mucosa of chronic inflammation. Ultrasonography indicates: Peritoneal effusion, pelvic effusion, left renal calculus, left hydronephrosis, cystic and solid mass in the left hydronephrosis, uterus and double accessories normal; CT diagnostic points: (1) cysts in the lateral segment of left liver lobe. (2) The left kidney atrophy, a substantial part of calcification, small cyst in polar front left kidney, the left Hydronephrosis. (3) Peritonitis change, involvement of bilateral rectus abdominis, with abdominal, pelvic effusion. (4) Left uterine calcification in the high density.

4 Primary diagnosis

- (1) The cause of ascites yet to be diagnosed:
 - Bacterial peritonitis?
 - Peritoneal mesothelioma?
 - Peritoneal metastatic carcinoma?
 - Tuberculous peritonitis?
- (2) Essential hypertension, Grade 2
- (3) Psoriasis

5 Treatment

The patient was treated with cefoperazone sodium and sulbactam sodium for injection 2.0 g, iv, bid, and cefoperazone sodium and sulbactam sodium for injection 1.0 g, qd, peritoneal perfusion. Trial anti-infective therapy, and oral spironolactone tablets 40 mg, qd, and furosemide tablets 20 mg, qd for diuresis were employed. Intervals human albumin 10 g/times was given 2-3 times a week to improve

colloid osmotic pressure and to maintain water-electrolyte balance, followed by nutritional treatment for half a month. Although the ascites amount was decreased after the treatment, the symptom of abdominal distension was not relieved, and the mass at the abdominal wall was not reduced. Consequently, yellowish turbid ascites (1,000 ml) by puncture was extracted, and was tested by ascites routine, showing the significant increasing of white blood cell (mainly the lymph cell). Biochemistry examination indicates exudate. Pathological examination of cells from ascites concluded the diagnosis of malignant tumor (pattern unknown). But it came with some difficulties to decide whether the tumor is primary peritoneal carcinoma (PPC) or peritoneal metastatic carcinoma, so PET-CT examination was required for an accurate diagnosis. Her past PET-CT examination in Beijing Friendship Hospital indicated the tumor to be peritoneal mesothelioma with lymph node metastasis in left inguinal. The patient then underwent laparoscope examination in general surgery department of our hospital, which presented yellowish ascites and nodular masses of varying sizes in the peritoneum and intestinal wall. The nodular masses were indicated to be tumor nodes (pattern unknown see Figure 1) in accordance with pathological examination. She was receiving a perfusate of cisplatin (20 mg) twice a week in our hospital. After the treatment for 3 courses, the patient was discharged since the symptom of abdominal distension was alleviated and the ascites was decreased. Follow-up examination after 3 months showed that the enlarged lymph nodes disappeared, the mass on abdominal wall reduced obviously, mild to moderate ascites in the abdominal cavity, and she also felt slight abdominal distension. Continuous treatment of cisplatin was given for another 3 courses. She felt that the symptom was mitigated without any discomfort during follow-up visits.

6 Discussion

6.1 Dr. Hao-shu Niu

Dr. Hao-shu Niu is an attending doctor in the Department of Gastroenterology of the Third Affiliated Hospital of Inner Mongolia Medical University, whose research interests are diagnosis and prevention of gastrointestinal diseases and gastrointestinal cancer precancerous lesions.

The patient was admitted to our hospital due to abdominal distension. Shifting dullness test was positive and ultrasonography indicates peritoneal effusion, establishing the diagnosis of ascites. In the abdominal cavity, there is usually a small amount (< 200 ml) of liquid acting as lubricant for intestinal peristalsis. It is then called ascites when the pathological accumulation of fluid in the peritoneal cavity is more than 200 ml. The key factors involve in the pathogenesis formation are hypoalbuminemia, hyponatremia, water retention, lower inactivation function of anti-diuretic hor-

none and aldosterone, portal hypertension, hepatic venous outflow obstruction, peritonitis and malignancies. Common transudative ascites are (1) hepatic ascites (2) malnutrition ascites (3) nephrogenic ascites (4) cardiac ascites (5) gastrointestinal ascites (6) vein occlusion with ascites (7) myxedema ascite. Common exudative ascites are (1) inflammation of the peritoneal (2) pancreatic ascites (3) ascites due to gallstone (4) chyloform ascites (5) cancer ascites.

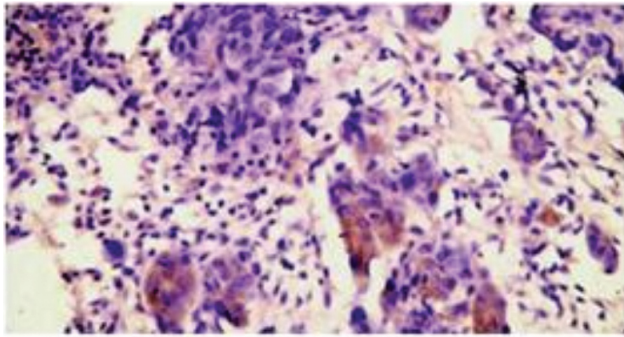


Figure 1: Pathology light microscope images ($\times 40$)

The patient underwent abdominal puncture, which confirmed the peritoneal fluid to be exudate. CT scan of abdomen revealed that no changes occurred in liver cirrhosis. Liver function and blood test were normal, and no evidence showed the causal relationship of liver cirrhosis with peritoneal effusion and primary peritonitis. Data from physical examination indicated that the patient was not infected with TB. PPD test is normal and no tubercle bacillus of the ascites was found in the abdominal cavity, so the diagnosis of tuberculous peritonitis was denied. Although ascites routine demonstrated the obvious increasing of white blood cell count, the patient showed no response to antibiotic therapy, with culture-negative bacterial ascites, so the diagnosis of spontaneous bacterial peritonitis was denied as well. The elder female patient was presented with abdominal distension and ongoing emaciation. Masses of different sizes, firm quality, uneven surface, with poor activity and ill-defined margins were found in abdominal cavity on physical examination. Ascites routine and biochemistry test proved the ascites to be exudate, and meanwhile highly raised levels of tumor markers were detected, and malignant cells by ascites pathology were discovered. Based on the data from the examination, laparoscope coupled with PET-CT scan affirmed the diagnosis of peritoneal mesothelioma.

6.2 Dr. Mao-lin Wang

Dr. Mao-lin Wang is an attending doctor in the Department of Gastroenterology of the Third Affiliated Hospital of Inner Mongolia Medical University, whose research interests are ERCP in diagnosis and treatment of biliary and pancreatic diseases.

Peritoneal mesothelioma is a rare type of cancer that occurs in mesothelium cells. It was first described in 1908 by Miller and Wynn, most occurs in the 40-60 years old age group, in which men are reported to be more likely infected than women. The overall prevalence is 1-2 cases per million^[1] with an increasing trend in recent years. Malignant peritoneal mesothelioma accounts for 0.067% of all malignant tumors, approximately one fifth to one third^[2] of all mesotheliomas cases diagnosed, and its proportion in all mesotheliomas is increasing gradually. The role of asbestos dust in the development of peritoneal mesothelioma is well established.^[3] Therefore, the risk of development of peritoneal mesothelioma is higher (> 66%) for anyone with increased years of exposure to asbestos than those not.^[4] Latency between exposure to asbestos and the development of peritoneal mesothelioma symptoms can range anywhere from 20-40 years. Exposure to asbestos is identified as the primary cause of peritoneal mesothelioma according to epidemiological studies. There is no enough evidence showing how the asbestos causes the disease, the direct effect on mesothelial cells, or the combination effect of reactive oxygen species and growth factors. It is demonstrated that the interaction between asbestos and mitotic spindle may result in the formation of haploid and the damage of chromosome.

However, no cases had been reported previously in individuals with any known exposure to asbestos. In addition to asbestos, virus, radioactive materials and chronic peritonitis are also the factors that contribute to the development of peritoneal mesothelioma on the basis of domestic studies.^[3]

There are no standard views regarding the tissue origin of mesothelioma. Some researchers hold the belief that mesothelioma develops from mesothelium cells. Some believe that epithelial mesothelioma stems from mesothelial cells and fibrous mesothelioma stems from connective tissue cells. While other researchers also think that mesothelioma originates from primary mesothelium cells. Based on electron microscopy and cell culture test, the views that mesothelioma from multipotent mesenchymal cells is gradually widely accepted recent years.^[5] As the onset of peritoneal mesothelioma is subtle, with no specific clinical presentation, multiple symptoms are the main clinical features.^[6] Patients with peritoneal mesothelioma are mostly presented with abdominal distension or pain, ascites and abdominal mass, in which abdominal mass accounts for 78% and ascites accounts for 88% respectively according to Deyin Peng's reports. The clinical cases show that both localized and diffuse peritoneal mesothelioma lead to the formation of ascites, while the latter is rare. Ascites is generally straw yellow or bloody, contains rich amount of HA and exfoliated cells of the tumor. The adhesion of visceral and parietal peritoneum in the advanced stage leads to the formation of encapsulated effusion. In addition, weight loss, anorexia, fatigue, nausea, vomiting are the most common symptoms during the advanced stage. It is generally believed that peritoneal mesothelioma grows along the sur-

face of peritoneum, developing plate-like samples that cover the viscera and parietal peritoneum in the abdominal cavity, with less deep infiltration of organs and lymph node metastasis. Autopsy cases analysis by Deyin Peng.^[7] demonstrates that the incidence of lymphatic and hematogenous metastasis is 50%-70%.^[2] He also describes systematic metastasis of peritoneal mesothelioma, and the incidence of metastasis outside abdominal cavity is 50%. Therefore, it indicates that growth pattern of peritoneal mesothelioma is expansive more than infiltrating on peritoneal surface, which serve as an important biology characteristic. Like other malignancies, peritoneal mesothelioma also has a tendency of local infiltration, implantation metastasis, lymphatic and hematogenous metastasis. In some reports state, there is no casual relationship between ascites amount and the extent of tumor invasion, and liver and lymph node metastasis incidence is relatively high.^[8] The extensive adhesion between enteric cavity and visceral cavity would stir up intestinal obstruction, and deep infiltration into the organ may cause ulcer or perforate.

The most common symptom at presentation is abdominal distension when the patient was admitted to our hospital. Her physical examination showed an abdominal mass and ascites. She was diagnosed with peritoneal mesothelioma according to ultrasonography, CT, laparoscopy, and PET-CT examination. Uncareful and noncomprehensive physical examination may lead to missed diagnosis and misdiagnosis of peritoneal mesothelioma since its symptoms are rare and atypical. A thorough examination is essential when the patients are presented with abdominal distension, abdominal pain and other atypical symptoms. If abdominal mass and ascites were seen in the physical examination, additional examinations of ultrasonography, CT, laboratory test of ascites, and tumor marker tests are necessary. A laparoscopy examination is needed for prevention of misdiagnosis of peritoneal mesothelioma when the symptoms appeared of unknown origin. Although diagnosis of peritoneal mesothelioma is challenging in its earlier stage, detailed medical history, careful physical examination, wide diagnostic thoughts and timely laboratory examination can significantly lower misdiagnosis rate.

6.3 Dr. Hong Cui

Dr. Hong Cui is an associate professor in the Department of Gastroenterology of the Third Affiliated Hospital of Inner Mongolia Medical University, whose research interests are diagnosis and treatment of gastrointestinal diseases under digestive endoscopy.

The clinical symptoms of peritoneal mesothelioma are atypia, so it is difficult to distinguish peritoneal mesothelioma from peritoneal metastatic tumor, tuberculosis peritonitis, retroperitoneal tumor, pancreatic tumor and cirrhosis ascites, which might lead to misdiagnosis. Ultrasonog-

raphy and CT scan of abdomen usually serve as useful tools to assist in the precise diagnosis of lesion site, size, cystic and solid mass, amount of ascites, and are helpful to identify digest tract, female genital tract tumors and ovarian cancer. The primary clinical manifestations are peritoneal thickening, heterogeneity mass in peritoneal cavity and ascites, but they are not specific.^[9] CT findings of peritoneal lesions in the earlier stage are not sufficient to arrive at a diagnosis. Other physicians, including Wuxiang Zheng.^[10] believe that a certain appearance of CT findings could be detected in localized peritoneal mesothelioma. (1) A large cystic and solid mass was found in peritoneal cavity, pelvic cavity and retroperitoneum, cystic mass accompanied with cystic cavity formed, partial cyst wall of uneven thickness, and mural nodes presented. (2) The solid nature of the tumor was intensified. (3) The tumor invaded other organs without distant metastasis and ascites. CT findings could reveal the lesion site when the greater omentum and mesenterium thickened widely. The primary appearance of CT scan is that irregular thickening emerges, adipose tissue is replaced by soft tissue tumor, the greater omentum develops into a "pie-like" mass, and the mesenterium into a "star-like" and "fold-like" mass, which are the same symptoms of overran tumor and tumor metastasis in peritoneal cavity.

Based on Shaojie Qiu's^[11-13] respective analysis, the paper summarizes imaging features highly suggestive of peritoneal mesothelioma (see Figure 2). (1) The imaging appearance when the tumor invaded parietal peritoneum: diffused or localized peritoneum, thickening of regular or irregular nodule, with non-even low echo, manifestation of "placenta" against ascites. (2) The imaging appearance when the tumor invaded visceral peritoneum: intestinal canal wrapped by thickened peritoneum, part of the inflatable loops of intestinal canal wrapped into "gas-bearing" mass, pseudokidney sign or target ring sign, the central part with strong echo, and the surrounding with solid low echo, intestinal adhesion fixed and poor activity, the greater omentum was "pie-like" thickening or forming into a large lesion. (3) Moderate to severe ascites, and interleaved fibrinoid with separate echo in part ascites. The mass in the pelvic cavity carries cystic-solid echo among female patients, characterized by internal mesh-like flow, indicating rich blood flow within the mass of malignant mesothelioma.^[14]

Ascites cytology provides valuable information in confirming the cell site of peritoneal mesothelioma. Diagnostic procedures in which fluid is extracted from the peritoneum for lab testing are essential to diagnose peritoneal mesothelioma. Pathological examination of abdominal ascites, therefore, would be of great importance in improvement of positive cytology rate if the patient could turn over several times before the testing sample taken. It is necessary to distinguish exfoliated cells of peritoneal mesothelioma, reactive methothelium and metastatic tumor cells. Biopsy is a quick and effective diagnosis approach for peritoneal mesothelioma under local anesthesia.

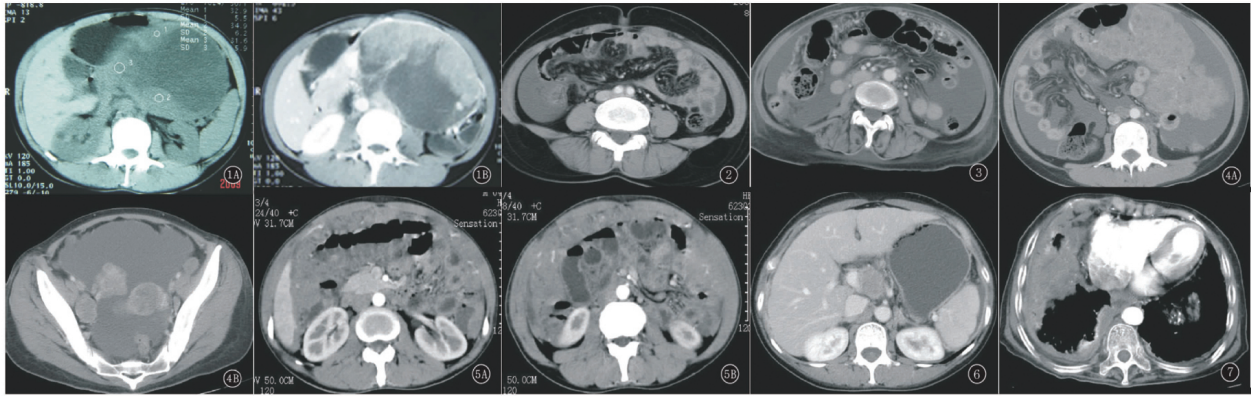


Figure 2: Figure 2-1): A,B. Cystic and solid mass (mainly cystic component) in left upper abdomen, oval-shaped, wall thickness varies, the solid part strengthened after enhancement (localized peritoneal mesothelioma); Figure 2-2): Irregular thickening of mesentery, beaded change, nodes in mesentery; Figure 2-3): Diffused peritoneal mesothelioma, irregular thickening of mesentery, the greater presented with short strips, patchy, nodular, dirt-like soft tissue density; Figure 2-4): A,B. Diffused peritoneal mesothelioma. Peritueum, the greater omentum, mesentery presented with irregular thickening with extensive nodular lumps of soft tissue density, changed significantly after enhancement; Figure 2-5): A,B. Diffused peritoneal mesothelioma. “pie-like” thickening of the greater omentum, obvious intensify, distorted vascular imaging increased; Figure 2-6): Diffused peritoneal mesothelioma accompanied with retroperitoneal lymph nodes; Figure 2-7): Diffused peritoneal mesothelioma complicated by pleural thickening and calcification

The clinical appearances of peritoneal mesothelioma under laparoscope are gray-white nodules of different sizes, with undefined amount, scattering on parietal peritoneum and gastric serosa. The less amounts of the nodules are, the most accurate diagnosis of peritoneal mesothelioma is, since all the patients with peritoneal mesothelioma share the same symptoms. The thickening of corpus callosum was clearly presented, and the adhesion between the parietal peritoneum and the organs in the peritoneal cavity is relatively light, with greater omentum and mesenterium involved. Mass of varying sizes, darker color, with significant congestion and edema could be seen in the abdominal cavity in most cases. The distribution of lesions may be either localized or diffused. Turbid ascites of different colors, including yellow, brick red, bright red, could be visualized as well. The literature on known cases of peritoneal mesothelioma suggests that serum, hgaluronic acid in the ascites, and CA125 is useful in the diagnosis of the disease.^[15] Some researchers also proposed the fact that malignant peritoneal mesothelioma could generate a large amount of hgaluronic acid, which is thought to be the principle diagnosis indicator of peritoneal mesothelioma.

There are several ways to classify peritoneal mesothelioma. Localized and diffuse types are the main classification of peritoneal mesothelioma according to Klemper and Robin’s description in 1931. Diffuse peritoneal mesothelioma is usually malignant and is much more widely seen in clinical practice than localized counterparts. Localized type could be benign or malignant when the diagnosis is made. A large number of cases demonstrate the presentation of firm tumor nodules of different sizes at the peritoneal surface,

and the tumor nodules can sometimes develop into a large mass. The organs in the abdominal cavity, then, would be surrounded with those white firm tumor tissues in the advanced stage, forming “frozen peritoneal cavity”. peritoneal mesothelioma also grow with patterns like solid, cystic and solid, and multicystic, or localized, diffused, diffused nodular, and cystic type. It could be divided into epithelial, fibrous and mixed type in accordance with WHO classification. The clinical manifestation of epithelial is diversified, such as tubular papillary cells, adenoid cystic carcinoma tumor or signet-ring cell tumours, *etc.* Some cases show the chondrometaplasia in fibrous peritoneal mesothelioma. More often, areas showing features and admixtures of these two types may be encountered within a single tumor, known as mixed peritoneal mesothelioma. Mixed type is the majority of all peritoneal mesothelioma cases that diagnosed in our country, and epithelial type are mostly diagnosed at abroad. Asbestos exposure is generally believed to be the most primary factor causing mixed peritoneal mesothelioma, but no cases of peritoneal mesothelioma by asbestos exposure were discussed in the domestic studies. Therefore, the real reason behind it remains to be further investigated.

6.4 Dr. Ji Chen

Dr. Ji Chen is an an associate professor in the Department of Gastroenterology of the Third Affiliated Hospital of Inner Mongolia Medical University, whose research interests are diagnosis and treatment of gastrointestinal diseases under digestive endoscopy and hepatobiliary disease diagnosis.

Current treatment of malignant peritoneal mesothelioma is

far from satisfactory. Early diagnosis and surgery treatment of localized peritoneal mesothelioma remains imperative for possible recovery, no matter it is benign or malignant. Benign peritoneal mesothelioma usually carries good prognosis, but it has a high tendency to recur locally, and consequently surgery is required to resect the reoccurrence. It is very difficult to obtain complete resection of diffuse peritoneal mesothelioma due to its wide lesion size. After the introduction of peritoneal stripping, cytoreductive surgery followed by intraperitoneal hyperthermic perfusion, a significant prolongation in the median survival has been achieved.^[16] The Advantage of intraperitoneal chemotherapy lies in the fact that it could greatly enhance drug concentrations in the peritoneal cavity and decreased systemic toxicity. Cisplatin chemotherapy after peritoneal absorption, meanwhile, can increase drug concentration in vein. Chemotherapy in the peritoneal surface by free diffusion combined with absorption function of blood capillary received a better outcome than intravenous chemotherapy. The complete remission rate of cisplatin is 59% with high reoccurrence, which suggests the fact that a complete resection of the tumor is impossible by cisplatin alone.^[17] Cytoreductive surgery followed by intraperitoneal hyperthermic perfusion seems to be a standard treatment for peritoneal mesothelioma, with overall median survival rate of 1, 3 and 5-year are 43%-88%, 43%-70%, 33%-68%^[18] respectively. In addition, cisplatin and mitomycin were mostly used for intraperitoneal chemotherapy, with 5-year disease-free survival rate 10%.^[2]

Surgical debulking followed by intraperitoneal chemotherapy is reported to significantly prolong survival to be 31 to 34 months. 2-year survival rate after complete cytoreductive surgery and early postoperative intraperitoneal chemotherapy is 79%. It is 44.7% for patients treated with surgery and intraperitoneal chemotherapy without a complete resection. Drug regimens (MMC, DDP, and/or MMC, ADM) used for intraperitoneal chemotherapy in the treatment of peritoneal mesothelioma by Dr. Deraco turned out to be very effective, with a median survival rate reported of 69% at 3 years. Systemic chemotherapy is receiving an increasing attention after that. Data from clinical cases suggests that pemetrexed in combination with cisplatin is optimal treatment for unresectable peritoneal mesothelioma. In general, the effect of radiotherapy on pleural mesothelioma is better than that on peritoneal mesothelioma, but there is a certain sensitivity.

Summary: diagnosis points of peritoneal mesothelioma: (1) Medical history: Past history of exposure to asbestos is required. (2) Symptoms: Clinical symptoms are abdominal distension or pain and abdominal mass, some patients are also presented with emaciation, decreased appetite, fatigue, nausea or vomiting. (3) Ascites and abdominal mass of unknown origin. (4) Ultrasonography scans: Peritoneal mesothelioma should be taken into consideration when the ultrasonography shows a large mass of irregular shape and

maldistribution with low echo, connecting to peritoneum without other organs involved. The following ultrasonography findings that help with the diagnosis of peritoneal mesothelioma could not be ignored as well: 1) The extensive thickening of visceral peritoneum and parietal peritoneum combined with ascites are the indicators of the disease. 2) Nodular thickening of sheet-like greater omentum and preperitoneum, and ascites with low light-spot or adhesions band of light. 3) Accompanying sign: the tumor could compress the convolutions, leading to the crowded distribution of convolutions around the tumor. It may cause enteric cavity narrow, incomplete intestinal obstruction, partial intestinal canal fixed and mesenterium thickening when the compression is intensified. (5) CT findings: The tumor could invade other organs without distant metastasis and ascites. CT findings could reveal the lesion site when the greater omentum and mesenterium thickened widely. The primary appearance of CT scan is that irregular thickening emerges, adipose tissue is replaced by soft tissue tumor, the greater omentum develops into a "pie-like" mass, and the mesenterium into a "star-like" and "fold-like" mass, which are also the same symptoms of overran tumor and tumor metastasis in peritoneal cavity. (6) Level of CA125 and CEA is increasing in serum markers and ascites. (7) Ascites cytology. It is useful tool to yield the diagnosis of peritoneal mesothelioma. (8) Laparoscopic-guided biopsy.

7 Conclusion

Peritoneal mesothelioma is a rare type of cancer, characterized by atypia, without specific imaging finding in CT and ultrasonography scan. A definitive diagnosis of peritoneal mesothelioma depends mostly on pathological diagnosis. Laparoscopic-guided biopsy, however, is complicated and it is not widely accepted among patients, which results in misdiagnosis. Besides that, the overall prognosis of malignant peritoneal mesothelioma is poor due to limited knowledge, rapid progression and high tendency of reoccurrence. A detailed medical history is required, and abdominal sign, shifting positive test combined with abdominal palpation during the physical examination should be paid more attention to prevent the misdiagnosis rate. Routine diagnostic examination of ascites, biochemical test, pathology of exfoliated cells from ascites, and serum tumor markers seem essential. Laparoscopic-guided biopsy may be needed if abnormal peritoneal thickening and mass changes were detected on the basis of a complete CT and ultrasonography scan, which significantly decrease the misdiagnosis rate. Early perfusion chemotherapy is much preferred to improve survival and prognosis in the treatment of peritoneal mesothelioma once the diagnosis is established. The effect of surgical treatment is relatively worse comparing with the perfusion chemotherapy.

References

- [1] Britton M. The epidemiology of mesothelioma. *Semin Oncol*. 2002 Feb; 29(1): 18-25. PMID:11836665. <http://dx.doi.org/10.1053/sonc.2002.30237>
- [2] Sugarbaker PH, Acherman YI, Gonzalez-Moreno S, *et al*. Diagnosis and treatment of peritoneal mesothelioma. *Semin Oncol*. 2002 Feb; 29(1): 51-61. PMID:11836669. <http://dx.doi.org/10.1053/sonc.2002.30236>
- [3] Xiaodan Huang, Guozhong Ji. Research progress of epithelial-mesenchymal transformation in tumor invasion and metastasis. *Journal of Medical Postgraduates*. 2010; 23(3): 319-322.
- [4] Welch LS, Acherman YI, Haile *et al*. Asbestos and peritoneal mesothelioma among college-educated men. *Occup Environ Health*. 2005; 11(3): 254-258.
- [5] Lin Dong-mei, pathomorphological observation of Mesothelioma. *Chinese Journal of Medicine*. 1999; 34(1): 33-37.
- [6] Haber SE, Haber JM. Malignant mesothelioma: a clinical study of 238 cases. *Ind Health*. 2011; 49(2): 166-172. PMID:21173534. <http://dx.doi.org/10.2486/indhealth.MS1147>
- [7] Deying Peng. Domestic Peritoneal Mesothelioma Diagnosis analysis of 236 cases. *Chinese Journal of Clinical Oncology and Rehabilitation*. 1996; 3(2): 73-75.
- [8] Ji YP, Kyoung WK, Heon JK, *et al*. Peritoneal mesothelioma: clinicopathologic feature, CT findings, and differential diagnosis. *AJR*. 2008; 191(3): 814-825.
- [9] Krasuski P, Poniecka A, Gal E. The diagnostic challenge of peritoneal mesothelioma. *Arch Gynecol Obstet*. 2002 Jul; 266(3): 130-2.
- [10] Xiangwu Zheng, Enfu Wu, Weiwei Yin, *et al*. Limitations of malignant Peritoneal Mesothelioma Diagnosis of CT and pathology. *Chinese Journal Of Radiology*. 2001; 35(1): 60-62.
- [11] Qiuji Shao, Guilian Qin, Wenyan Shi, *et al*. Ultrasonographic manifestations and diagnosis value of peritoneal Malignant mesothelioma. *Chinese Journal Of Medical Imaging Technology*. 2007; 23(2): 246-248.
- [12] Qing Xie, Xiaoying Lei, Chunying Liu *et al*. Ultrasonographic characteristics of Peritoneal Mesothelioma. *Journal Of Ultrasound In Clinical Medicine*. 2008; 10(6): 411-413.
- [13] Yandan Sun, Jinming Wang, Xuehong Yuan, *et al*. Clinical value of ultrasonography in the diagnosis of peritoneal Malignant mesothelioma. *Medical Journal of West China*. 2009; 21(10): 1787-1788.
- [14] Shaoyu An, Jian Liu, Ke Tian, Liu Jun, Qiuxin Wei. Clinical characteristics of female pelvic Peritoneal Mesothelioma and Characteristic Analysis of Color Doppler ultrasound images. *Biomedical Engineering And Clinical Medicine*. 2011; 05: 427-430.
- [15] Baratti D, Kusamura S, Martinetti A, *et al*. Circulating CA125 in patients with peritoneal mesothelioma treated with cytoreductive surgery and intraperitoneal hyperthermic perfusion. *Ann Surg Oncol*. 2007; 14(2): 500-508. PMID:17151789. <http://dx.doi.org/10.1245/s10434-006-9192-8>
- [16] Brigand C, Monneuse O, Mohamed F, *et al*. Peritoneal mesothelioma treated by cytoreductive surgery and intraperitoneal hyperthermic chemotherapy: results of a prospective study. *Ann Surg Oncol*. 2006; 13(3): 405-412. PMID:16485159. <http://dx.doi.org/10.1245/ASO.2006.05.041>
- [17] Deraco M, Casali P, Inglese MG, *et al*. Peritoneal mesothelioma treated by induction chemotherapy, cytoreductive surgery, and intraperitoneal hyperthermic perfusion. *J Surg Oncol*. 2003 Jul; 83(3): 147-153.
- [18] Baratti D, Kusamura S, Deraco M. Diffuse malignant peritoneal mesothelioma: Systematic review of clinical management and biological research. *J Surg Oncol*. 2011; 103(3): 822-831. PMID:21283990. <http://dx.doi.org/10.1002/jso.21787>