

CASE REPORTS

Diagnosis and treatment of Wilms tumor

Changjiu Yue*, Zhizhong Liu, Lizhong Han, Wenjun Cao

Department of Urology, The Third Affiliated Hospital of Inner Mongolia Medical University, Baotou, China

Received: May 15, 2015

Accepted: July 20, 2015

Online Published: September 10, 2015

DOI: 10.14725/dcc.v2n3p26

URL: <http://dx.doi.org/10.14725/dcc.v2n3p26>

Abstract

We collected a medical record of “Wilms’ tumor” in the Department of Urology at the Third Affiliated Hospital of Inner Mongolia Medical University, and discussed the diagnosis, auxiliary examination and treatment of the disease. We hope to expand clinical thinking, improve our diagnosis and treatment of the disease through data analysis.

Key Words: Wilms’ tumor, Diagnosis, Treatment

1 Medical records

1.1 General information

A 7-year-old boy was admitted to our hospital on May 29, 2013 due to low back pain for a whole day. The patient suffered from persistent dull pain at low back on the day of admission with especially pain at the left part. He had no significant symptoms of loose pain, urinary frequency, urgency, dysuria, gross hematuria or fever. The urine routine examination showed RBC (3+), PRO (+). We finally received the patient as “microscopic hematuria” for further diagnosis and treatment.

1.2 Physical examination

T 37°C, P 84 beats/min, blood pressure 110/85 mmHg. The lungs were clear to auscultation bilaterally, without any wheezes, rales, or rhonchi. The heart rate was 84 beats/min, showing regularity in the force and rhythm of the heartbeat. On the left side of the abdomen was full, tenderness, without bounce painful. Left renal percussion pain was positive. Both lower extremities were not swollen.

1.3 Auxiliary examination

CT examination (see Figure 1): A large circular abnormal density shadow could be seen in the left kidney region, the maximum diameter was 10 cm × 7.5 cm. The boundary was still clear with intact capsule and mixed internal density, and the lesion was not clear between the local and the surrounding tissue. Enhanced scan of the left renal lesion showed significant uneven enhancement. There was a long line of low density shadow near the left kidney. The right kidney was normal in size and shape. The density of the parenchyma was uniform, and there was no abnormal tissue density and space occupying lesions.

Chest radiograph: No obvious abnormal changes were found in heart and lung diaphragm.

Routine urine test: RBC (3+), PRO (+); urine red blood cell morphology: 50-70/1,000-fold of centrifugal urine erythrocytes were observed under phase contrast microscope, the rosette like erythrocytes accounted for 77%, the shadow cells accounted for 23%, and more white blood cells were seen; 24 hrs urine protein: 0.34 g/24 hrs.

Routine blood test: WBC count $13.92 \times 10^9/L$, neu-

*Correspondence: Changjiu Yue; E-mail: yuechangjiu@163.com; Address: The Third Affiliated Hospital of Inner Mongolia Medical University, Baotou, China.

trophil percentage 84.01%, lymphocyte percentage 10.92%, hemoglobin 130 g/L, platelet count $359 \times 10^9/L$, ESR 38 mm/h of blood electrolytes, liver function and renal function were normal.

The clinical bone metastasis of nephroblastoma was very rare, and the isotope bone marrow scan was not routinely examined.

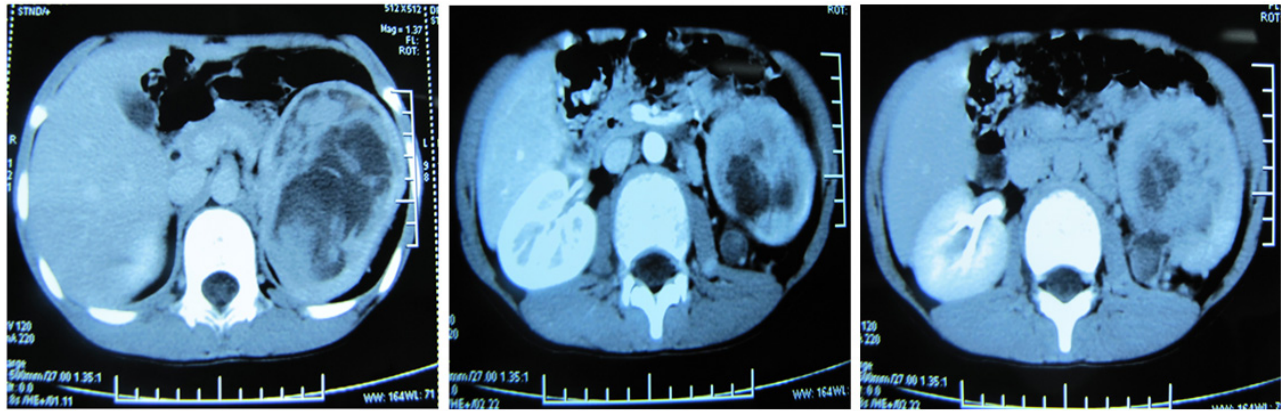


Figure 1: Left renal cell tumor (left kidney area showed a large round abnormal density, the integrity of the kidney damage, the tumor mass common cystic necrosis boundary was still clear, the density of hybrid, lesion and surrounding tissue has no clear boundary, the enhanced scan showed obvious inhomogeneous enhancement in the left renal focus)

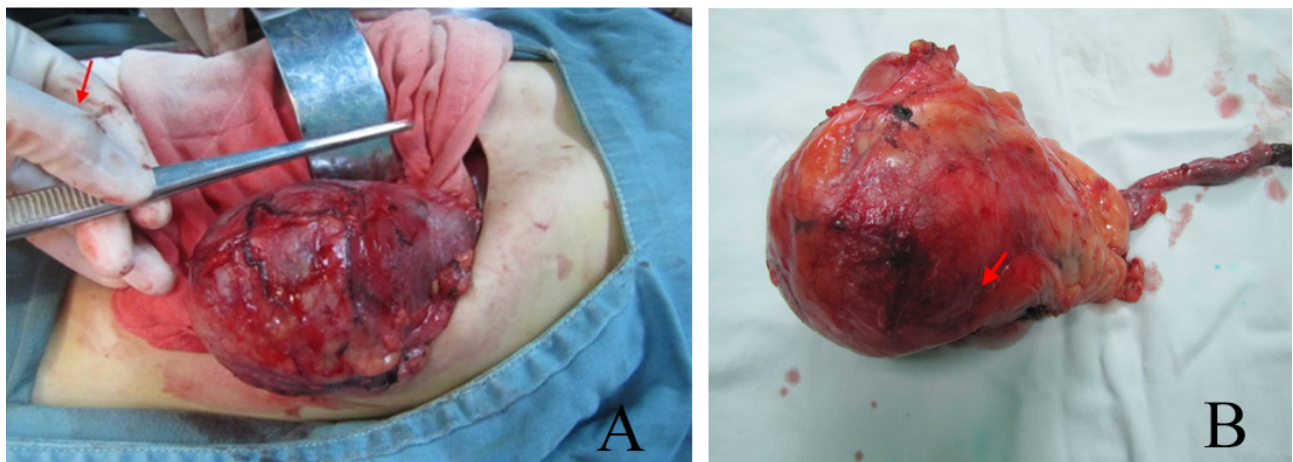


Figure 2: Intraoperative condition and size of the resected specimen

1.4 Preliminary diagnosis

Wilms' tumor (WT) (see Figure 2).

1.4.1 Diagnosis and treatment

Patients had fever with body temperature up to 39.6 °C, hematuria and lumbago. Anti-inflammation treatment was performed while B ultrasound and CT examination were taken at the same time. All these symptoms were suggestive of left renal WT. The patient's body temperature has

decreased, but not to normal. Left renal WT resection was operated under general anesthesia. During the operation, the tumor and the surrounding adhesions were found adhesive. The tumor, kidney and perirenal fat were removed carefully. The enlarged lymph nodes near the abdominal aorta were found, and the renal pedicle and abdominal aortic lymph nodes were removed. The patient's temperature gradually decreased to normal and the patient recovered well. Pathological findings (see Figure 3): (left) WT, left ureter end cut, renal hilar vascular tissue not invaded, (left kidney, abdominal aorta) lymph node metastasis not seen (0/1, 0/17).

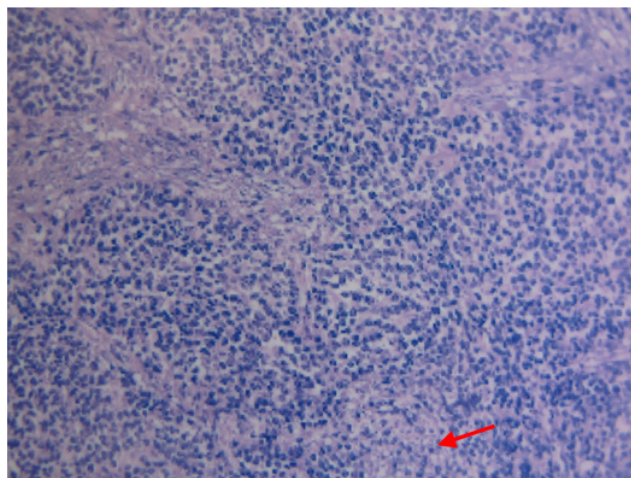


Figure 3: Pathology: nephroblastoma

2 Discussion

2.1 Dr. Zhizhong Liu

Zhizhong Liu, a chief physician of Department of Urology at the Third Affiliated Hospital of Inner Mongolia Medical University, specializing in kidney transplantation, laparoscopy and minimally invasive techniques.

WT, also known as nephroblastoma, is a malignant mixed solid tumor derived from embryonic renal tissue, and comprising mesenchyme, epithelium and blastemal. The epithe-

lium tissue constitutes the majority of the tumor, including glands, nerves, collagen connective tissue with different levels of differentiation, smooth muscle and striated muscle group fiber, fat and cartilage. It is the most common malignant tumor in the pediatric urinary system, accounting for 8%-24% of the malignant solid tumors in children.

WT can be divided into favorable histology (FH) and unfavorable histology (UH) by National Wilms Tumor Study Group (NWTSG) according to the histological features and cell differentiation. FH contains blastemal, mesenchymal, epithelial and mixed elements, while UH mainly refers to the anaplastic or undifferentiated elements. About 5% of WT were found in older children, with most cases seen around 5 years old.^[1] Approximately 12% of patients with WT have an underlying predisposing syndrome, such as incomplete orchiocatabasis, hypospadias, hemihypertrophy, and aniridia.^[2]

The vast majority of WT present with smooth surface asymptomatic abdominal mass, but substantial, without apparent tenderness on the side of the abdomen hypochondrium. Abdominal discomfort, irritability, shortness of breath, even the symptoms of acute abdomen may occur when the mass grows rapidly. About 25% patients had microscopic hematuria and 60% patients experienced different levels of hypertension due to the compression of renal artery.^[3] At present, the NWTS-3 staging method (see Table 1) proposed by the NWTS is widely used in clinical application of WT in our country.

Table 1: Children’s Oncology Group (COG) staging systems

Stages	
Stage I	Tumor is limited to the kidney and has been completely resected. The tumor was not ruptured or biopsied before removal. No penetration of the renal capsule or involvement of renal sinus vessels.
Stage II	Tumor extends beyond the capsule of the kidney but was completely resected with no evidence of tumor at or beyond the margins of resection. There is penetration of the renal capsule or invasion of the renal sinus vessels.
Stage III	Gross or microscopic residual tumor remains postoperatively including inoperable tumor, positive surgical margins, tumor spillage surfaces, regional lymph node metastases, positive peritoneal cytology, or transected tumor thrombus. The tumor was ruptured or biopsied before removal.
Stage IV	Hematogenous metastases or lymph node metastases outside the abdomen (e.g. lung, liver, bone, and brain).
Stage V	Bilateral renal involvement is present at diagnosis.

WT is the first to employ comprehensive treatment among all paediatric solid tumor, whose overall survival rate (25% treated by surgery only) gradually increased to 90% in recent years.^[4] Surgery maintains an important role in the treatment of WT, with the addition of radiotherapy and chemotherapy according to clinical staging and histopathological features. Hence, the role of surgery is critical in affecting the survival rate of patients with renal cell tumor. Moreover, postoperative standardized staging, timely combination of chemotherapy and radiotherapy are also important factors. Studies reported that one year survival rate of

patients treated with or without chemotherapy is 53% and 25% separately, showing statistical differences between two groups.^[5] Surgical methods include:

- (1) Conventional surgical method. Surgery is recommended as the primary treatment approach for patients with unilateral WT, regardless of pulmonary metastasis. At present, the most frequently used surgical procedure is partial nephrectomy for tumor in a solitary kidney.^[6] The advantages of the procedure are: 1) to allow adequate exposure and wide operative field; 2) be convenient for the

surgeon to explore the regional lymph nodes during the surgery, and to check metastatic spread to internal organs, and contralateral kidney, which is conducive to the removal of the retinopathy and related lymph nodes. I, II stage tumor enable the implement of complete resection, as well as III stage tumor. Complete resection should not be too much emphasized on advanced cancer. Postoperative chemotherapy and radiotherapy can remove the residual tumor tissue.^[7,8] NWTS disfavors formal lymph node dissection, and suspicious lymph nodes necessitates the pathological examination. Lymph node dissection does not improve survival rate, but increases the surgical complications.

(2) Partial nephrectomy.

The procedure is appropriate for solitary kidney, bilateral WT, or a combination of WT and other kinds of cancer, such as Beckwith-Wiedemann. The prerequisite for partial nephrectomy of unilateral WT: 1) preoperative chemotherapy confines the tumor to the limited space; 2) there is a clear boundary between the tumor, the kidney and the surrounding tissues; 3) the tumor occupies a small portion (< 1/3) of the renal parenchyma. The patients are eligible for partial nephrectomy without any involvement of renal vessels and collecting system invasion. Haecker et al.^[9] reported that the tumor-free rate for 37 cases of unilateral WT treated with preoperative chemotherapy prior to partial nephrectomy is 88%, showing no significant difference with the rate of 93% for 770 cases undergoing synchronous nephrectomy.

CT examination should be performed to guide fine needle aspiration biopsy prior to the surgery when the following conditions are met: (1) high-risk surgery: capsular tension, complete resection is difficult, or intraoperative rupture of the tumor may occur; (2) tumor thrombus to the level of the portal vein or the right atrium; (3) the occurrence of distant metastasis; (4) bilateral WT. For patients with the surgical risk, CT examination is required to guide fine needle biopsy for the diagnosis of the disease. The surgery is feasible in case of smaller mass, thickening capsule without distal metastasis and thrombus after two causes of preoperative chemotherapy. Chemotherapy and radiotherapy protocols based on clinical stages and histological classification are formulated after surgery.

2.2 Dr. Changjiu Yue

Changjiu Yue, the deputy director of Department of Urology at the Third Affiliated Hospital of Inner Mongolia Medical University, specializing in urology surgery and andrology.

We analyzed the application value of all imaging examinations in the diagnosis of WT.

Published by New Century Science Press

- (1) Ultrasound. The imaging shows a hypoechoic solid mass in the kidney. The mass causes damage to the integrity of the affected kidney, in which necrotic cyst is included. Color Doppler ultrasound revealed the tumors with rich blood supply. Pulse Doppler spectrum indicates high speed and high resistance artery like nourishing blood flow signal, with vascular resistance index (RI) > 0.63, showing higher diagnostic value. Sometimes, metastatic tumor emboli in the inferior vena cava is visible.
- (2) CT. CT plain scan is highly suggestive of the heterogeneity of mass with low density and necrotic area deriving from one side of the kidney. There is a small scattered tumor in the calcification, with a false membrane of the tumor, drawing a clear line with normal renal tissue. The enhanced scan is typically characterized by tumor erosion, compression of the kidneys, and the presence of residual kidney parenchyma with a thin, linear, or crescent-like enhanced.^[10] CT can determine the origin and extend of the tumor, the relationship with the surrounding tissues and organs, whether it exists double renal lesions or tumor metastases.
- (3) Though intravenous pyelography enables the surgeons to master the condition of renal function, renal pelvis and renal calices images are only relied to speculate the volume and location of the tumor. Moreover, 10% of the cases showed no images due to tumor invasion to renal tissue and renal vein. Ultrasound and CT carries more application value than intravenous pyelography.^[11]

The value of preoperative ultrasonography and CT in diagnosing WT lies in the following facts: (1) evaluates the contralateral kidney function, so as to correctly guide the contralateral nephrectomy; (2) displays the renal vein, inferior vena cava and right atrial metastasis of the tumor thrombus as well as the chest, abdominal metastases. Esophageal ultrasound can be used to reflect the condition of tumor thrombus (particularly high level thrombi) when necessary;^[12] (3) indicates the degree of tumor invasion and staging, and help confirm the best clinical treatment approach; (4) serves as a means of long-term follow-up and monitoring of recurrence. It has been reported that the sensitivity of the tumor to chemotherapy could be evaluated by the change of liquefied tumor necrosis, blood supply and volume, allowing quantitative and qualitative monitoring of other organs for preoperative chemotherapy.^[13] The lungs are the most common site of metastatic spread that occurs in 10%-15% of children with WT at the time of diagnosis. Therefore, CT of the chest should be treated as a routine examination.

Both adrenal neuroblastoma and WT are the most common malignant tumor in children. We could explore the differential diagnosis of the diseases based on the imaging data in

combination of literature. Neuroblastoma is a highly malignant tumor with no capsule and adjacent to surrounding tissues, composed of undifferentiated neuroblastoma cells.^[14] Neuroblastoma usually arises in the adrenal medulla and sympathetic ganglion, with slightly higher incidence in the left side than the right side. It is commonly seen in children under 5 years old,^[15] 80% occurs in children under 3 years of age. Ganglioneuroblastoma, also known as neuroblastoma differentiation, consist of neuroblastoma, differentiation of ganglion cells, proliferous Schwann cells and glial fibrillary, while malignant degree is lower than former.

The differences between WT and retroperitoneal neuroblastoma are: (1) firstly, the age of onset is relatively greater with lighter symptom in WT; (2) secondly, determination of catecholamine metabolites in urine and bone marrow examination are in favor of identification;^[16] (3) thirdly, CT examination for neuroblastoma is mainly manifested by renal compression displacement. Tumor necrosis and cystic change are rare, and the incidence of calcification (especially plaques and thick calcifications) is higher, which are easily differentiated from WT.^[16] WT arises from undifferentiated mesodermal tissue, which can occur in any part of the kidney, single or multiple, with rapid tumor growth. Usually, it has complete capsule, whose diameter ranges from 20 cm to 30 cm, showing clear demarcation with normal renal parenchyma. The tumor may contain necrosis, hemorrhage, calcification and cystic change. Enlarged tumor can directly invade surrounding renal tissues.^[17] CT is a valuable examination method in identifying adrenal neuroblastoma and WT.

2.3 Dr. Lizhong Han

Lizhong Han, a physician of Department of Urology at the Third Affiliated Hospital of Inner Mongolia Medical University, specializing in kidney transplantation and urology surgery.

WT is the most common renal tumor of childhood, and it is also a kind of solid tumor with good prognosis in children. NWTSG and International Society of Paediatric Oncology (SIOP) confirmed that individualized multidisciplinary treatment was the warranty of good prognosis. Currently, a number of international research centers focus on the study of renal cell tumor. Among them, SIOP was the first to propose the concept of preoperative chemotherapy, and studied the feasibility and effectiveness of approach.

It remains a controversy whether to carry out intravenous chemotherapy prior to the surgery. The two largest groups that have studied the optimal management of WT are SIOP and NWTSG. The SIOP approach favours pre-operative chemotherapy for all case except very young infants (< 6 months of age, unilateral disease). By contrast, the NWTSG recommends primary surgery before an adjuvant treatment. They also elaborates the importance of clinical

staging in suggesting tumor aggressiveness and accurate histological type, collecting biological information of untreated tumor molecular, and guiding postoperative adjuvant radiotherapy and chemotherapy.^[18] For NWTSG-4, needle biopsy prior to preoperative chemotherapy is recommended for bilateral WT (including solitary nephroblastoma).^[19]

The advances in preoperative chemotherapy are: (1) it can shrink the tumor and be conducive to tumor resection, reduce the complication rate and avoid the need of postoperative radiotherapy and chemotherapy;^[20] (2) it is especially suitable for large tumors, long segment vena cava tumor thrombus, and tumor invasion into main organs, which is not candidate for surgical resection. Planned preoperative chemotherapy is able to reduce the risk of surgery and improve the chance of complete resection. In addition, the tumor shrinks to limited extent after chemotherapy, avoiding surgical removal of more renal tissue, and is beneficial to preservation of the renal parenchyma,^[19] which is more valuable for bilateral and solitary kidneys; (3) the sensitivity of the tumor to preoperative chemotherapy can be used to determine the histological characteristics of the tumor, and to guide the postoperative chemotherapy and prognosis of patients with renal cell carcinoma.^[21] Change of other chemotherapy drugs is required if the tumor is not sensitive to preoperative chemotherapy drugs. And yet, it shows sensitive to chemotherapy and indicates good prognosis if the tumor is significantly reduced during preoperative chemotherapy.

Preoperative chemotherapy is not always beneficial. SIOP-9 demonstrated the misdiagnosis of 28 cases of WT of all 511 cases treated with preoperative chemotherapy (misdiagnosis rate accounts for 5%), of which 1.8% were benign lesions of the kidney.^[22] The prognosis of Stage II WT treated with or without preoperative chemotherapy is of no significant differences, thereby, enhancing the toxicity of chemotherapy and potentially provides for an extra increase in treatment charges.

Despite of the effect of down-staging, preoperative chemotherapy group has no significant differences with surgery group over resection rate, postoperative disease-free survival rate and overall survival rate. In addition, it may interfere with postoperative histological staging, facilitate an increased tendency of portal vein occlusion, and positively correlate with the dose of Actinomycin D (AMD).^[23,24] The patients, who are unresponsive to preoperative chemotherapy, would miss the optimal surgical timing if the tumor continues to grow during chemotherapy.

Currently, intravenous chemotherapy is a widely accepted approach. In view of low drug concentration and systemic drug toxicity of systemic chemotherapy in target tumor cells, arterial chemoembolization is highly recommended. It not only imposes less adverse effect, but also shortens the preoperative treatment from 4-6 weeks to 2 weeks. Besides, the approach can shrink the tumor significantly, and the de-

gree of necrosis is more obvious. In that case, a higher rate of achieving a complete resection of the tumor, and a higher rate of postoperative disease-free survival rate are expected.^[25]

SIOP 93-01 trials^[26] recommended the following preoperative chemotherapy: VA protocol (VCR+ATCD) for stages I-III for 4 weeks, VDA protocol (VCR+ACTD+ADM) for stage IV for 6 weeks. Yang Y et al.^[27] reported that surgical timing after chemotherapy was determined according to specific circumstances, such as shrank tumor in imaging, thickened capsule, and adjacent to important organ involvement improved. At the same time, the overall situation of children improved, usually 2-3 weeks after chemotherapy.

2.4 Dr. Wenjun Cao

Wenjun Cao, a chief physician of Department of Urology at the Third Affiliated Hospital of Inner Mongolia Medical University, specializing in urology surgery and andrology.

Rarely, WT may also present in the adult age group.^[28] It

remains a challenge for the surgeons to confirm the diagnosis of adult WT as the disease is more common in children. It is not uncommon for a firm mass to be discovered among pediatric patients due to the thinness of the abdominal wall and typical syndrome. However, there is no significant difference between the adult and paediatric WT in imaging performance, showing a solid or a cyst-solid mass. Color Doppler ultrasound is often highly suggestive of scattered light spots on the edges of tumors in children patients, which is rarely seen in adult WT cases.

The standard diagnostic criteria of adult WT must be met: (1) primary renal neoplasms; (2) the existence of primitive round-cell and spindle-cell; (3) the formation of immature or embryonic-like renal tubule, or pathological structure of glomerular; (4) no existence of renal carcinoma tissue; (5) clear histological images; (6) older than 15 years. At present, there are no uniform diagnostic criteria for immunohistochemistry.

Adult WT and renal cell carcinoma are easy to be confused, so differential diagnosis is required (see Table 2).

Table 2: Key points of distinguishing between adult WT and renal carcinoma

Adult WT	Renal carcinoma
Age: The age of onset of nephroblastoma in adults is relatively small, and is less than 40 years old.	Age: > 40 years old.
Tumor size: The size of the tumor is huge and the average diameter is > 10 cm.	Tumor size: tumor diameter is more than 10 cm, without capsule.
CT: The envelope is intact and the margin is clear. It is often a large mass, with a low density and uneven distribution of irregular cystic degeneration. There are occasional calcifications, which were linear peripheral calcifications or concentrated small pieces of calcification. The solid part of the scan masses showed a linear inhomogeneous enhancement in the normal renal parenchyma. The necrotic area was not enhanced in hemorrhagic or cystic areas. ^[29] The lesions showed less bloody, no arteriovenous fistula, and the vessels were thin and curved, forming “vine like” or “fine strip” vascular.	CT: It is a round or oval mass showing no clear boundaries with renal limit. After enhanced scan, the density of the lesion was low and slightly enhanced, while the density of normal renal parenchyma was markedly enhanced. The contrast between the two cases was obvious, and the lesions showed. The renal arteriography revealed abundant blood supply, and formation of arteriovenous fistula, pathologic vessel and neovascularization. Vascular disruption sometimes occurs. ^[30]

The prognosis of adult WT is worse than that of children. Some scholars believe that the tumor is often related to progression during adult WT treatment and over 50% cases are at stage III and IV. The histological classification of paediatric WT is also applicable for adult WT.^[31] At present, radical nephrectomy is the preferred treatment method, in combination with chemotherapy or radiotherapy at the same time.^[32] Based on the result of SIOP 93-01 trial treatment of 30 cases of adult WT, SIOP believes that better prognosis of adult WT could be achieved by therapeutic principle of WT in children. Four-year overall survival rate and disease-free survival rate were 83% and 57%, respectively. On account of the limited number of cases, there is no uniform treatment management of adult WT. Currently, treatment protocols of paediatric WT are widely employed by adult WT.^[33,34]

The paper also reviews the clinical performance and treatment condition of recurrent WT. Due to infiltrative growth pattern and resistance to chemotherapy, it remains a difficulty to carry out surgical resection and chemotherapy of recurrent tumors. Therefore, the prognosis is poor, and the disease-free survival rate of 2a is 43% to 70%.

WT is one of the most common solid tumors in children. The multidisciplinary approach (surgery, chemotherapy and radiology) to WT management has become an example of the success stories of paediatric oncology. While, there are pending clinical issues to be solved, including the treatment of unfavorable type, recurrence and metastasis and bilateral disease. NWTS-4 reported 188 cases of bilateral WT of 3,335 patients, accounting for 5.6%.^[35]

The current thoughts on management recommendations of bilateral WT are also reviewed in the paper. Surgery is a controversial management approach for patients with the disease. It was reported that^[36] bilateral WT was characterized by high incidence of renal failure, with 9% in synchronous bilateral disease, and 18% in successively bilateral WT. Therefore, the focus of controversy lies in the choice of the optimal timing of surgery and the protection of residual renal function. Renal failure is mainly caused by imperative bilateral renal resection for refractory or recurrent tumor, and other clinical treatments (such as chemotherapy, radiotherapy, surgical complications).

Hamilton et al.^[37] recommended preoperative chemotherapy for the children patients with bilateral WT to maximize the preservation of renal parenchyma, and bilateral tumor biopsy should be performed prior to chemotherapy. Re-assessment of the likelihood of preserving the renal function is made after chemotherapy for 5 weeks, afterwards the surgery is performed within 6 weeks. Xu M et al.^[38] deemed the best time of curative effect was 4-6 weeks after surgery. Insufficient normal renal tissues necessitate appropriate correction and prolongation of chemotherapy. In

a way, there is no significant difference between preoperative chemotherapy and I stage operation with respect to survival rate. By contrast, preoperative chemotherapy enables the possibilities of preserving more renal tissues. As for the need of surgery of residual disease, Xu M^[38] encouraged residual disease kidney required no reoperation resection if the renal function was preserved under non-complete resection. Residual tumor tissues, sometimes, are necrosis, fibrosis or other benign components other than live tumor cells. Follow-up observation is feasible for long-term survival with tumor.

In conclusion, the management of WT requires multidisciplinary input of paediatric surgeons, chemotherapy, radiologists, pathologists and radiation oncologists. In addition to the patient's stage, histological classification and individual difference, the treatment plan should be based on unified standard treatment principle in order to ensure its effective and safe implementation, and to improve the curative effect.

Conflicts of Interest Disclosure

The authors have no conflict of interest related to this article.

References

- [1] Green DM, Beckwith JB, Breslow NE, et al. Treatment of children with stages II to IV anaplastic Wilms' tumor: A report from the National Wilms' Tumor Study Group. *J Clin Oncol.* 1994; 12(10): 2126-2131.
- [2] Geller E, Kochan PS. Renal neoplasms of childhood. *Radiol Clin North Am.* 2011; 49(4): 689-709. PMID: 21807169. <https://doi.org/10.1016/j.rc1.2011.05.003>
- [3] Amel L, Leila BF, Lamia K, et al. Histologic and prognostic study of nephroblastoma in central Tunisia. *Ann Urol (Paris).* 2003; 37(4): 164-169.
- [4] Gao XC, Wang YP. Modern pediatric oncology. Shanghai: Fudan University press; 2003. 518-534 p.
- [5] Wilde JC, Lameris W, van Hasselt EH, et al. Challenges and outcome of Wilms' tumour management in a resource constrained setting. *Afr J Pediatr Surg.* 2010; 7(3): 159-162. PMID: 20859020. <https://doi.org/10.4103/0189-6725.70416>
- [6] Blakely ML, Ritchey ML. Controversies in the management of Wilm' tumor. *Semin Pediatr Surg.* 2001; 10(3): 127-131. <https://doi.org/10.1053/spsu.2001.24698>
- [7] Meyer JS, Harty MP, Khademian Z. Imaging of neuroblastoma and Wilms tumor. *Magn Reson Imaging Clin N Am.* 2002; 10(2): 275-302. [https://doi.org/10.1016/S1064-9689\(01\)00010-1](https://doi.org/10.1016/S1064-9689(01)00010-1)
- [8] Hill DA, Shear TD, Liu T, et al. Clinical and biologic significance of nuclear unrest in Wilms tumor. *Cancer.* 2003; 97(9): 2318-2326. PMID: 12712489. <https://doi.org/10.1002/cncr.11325>
- [9] Haecker FM, von Schweinitz D, Harms D, et al. Partial nephrectomy for unilateral Wilms tumor: results of study SIOP 93-01/GPOH. *J Urol.* 2003; 170(3): 939-942. PMID: 12913746. <https://doi.org/10.1097/01.ju.0000073848.33092.c7>
- [10] Gow KW, Roberts IF, Jamieson DH, et al. Local staging of Wilms' tumor-computerized tomography correlation with histological findings. *J Pediatr Surg.* 2000; 35(5): 677-679. PMID: 10813321. <https://doi.org/10.1053/jpsu.2000.5941>
- [11] Meyer JS, Harty MP, Khademian Z. Imaging of neuroblastoma and Wilms tumor. *Magn Reson Imaging Clin N Am.* 2002; 10(2): 275-302. [https://doi.org/10.1016/S1064-9689\(01\)00010-1](https://doi.org/10.1016/S1064-9689(01)00010-1)
- [12] Bar-Sela G, Arush MW, Reisner S, et al. Atrial metastasis detected by two-dimensional echocardiography. *Acta Oncol.* 2004; 43(1): 87-90. PMID: 15068325. <https://doi.org/10.1080/02841860310016910>
- [13] Schenk JP, Schrader C, Zieger B, et al. Reference radiology in nephroblastoma: accuracy and relevance for preoperative chemotherapy. *Rofo.* 2006; 178(1): 38-45. PMID: 16392056. <https://doi.org/10.1055/s-2005-858836>
- [14] Department of Pathology, Wuhan Medical College. Surgical pathology. Part II. Wuhan: Hubei people's publishing house; 1983. 1119-1122 p.
- [15] Li GZ. Clinical CT diagnosis. Beijing: Chinese science and Technology Press; 1994. 520-521 p.
- [16] Meyer JS, Harty MP, Khademian Z. Imaging of neuroblastoma and Wilms tumor. *Magn Reson Imaging Clin N Am.* 2002; 10(2): 275-302. [https://doi.org/10.1016/S1064-9689\(01\)00010-1](https://doi.org/10.1016/S1064-9689(01)00010-1)
- [17] Zhou KR. Abdominal CT. Shanghai: Shanghai Medical University Press; 1993. 173-174 p.
- [18] Metzger ML, Dome JS. Current therapy for wilms' tumor. *Oncologist.* 2005; 10: 815-826. PMID: 16314292. <https://doi.org/10.1634/theoncologist.10-10-815>
- [19] Hamilton TE, Ritchey ML, Haase GM, et al. The management of synchronous bilateral Wilms tumor: A report from the NWTSG. *Ann Surg.* 2011; 253(5): 1004-1010. PMID: 21394016. <https://doi.org/10.1097/SLA.0b013e31821266a0>
- [20] Israëls T, Molyneux EM, Caron HN, et al. Preoperative chemotherapy for patients with Wilms tumor in Malawi is feasible and efficacious. *Pediatr Blood Cancer.* 2009; 53(4): 584-589. PMID: 19533658. <https://doi.org/10.1002/pbc.22138>
- [21] Vujanic GM, Sandstedt B. The pathology of Wilms' tumour (nephroblastoma): The International Society of Paediatric Oncology approach. *J Clin Pathol.* 2010; 63(2): 102-109. PMID: 19687012. <https://doi.org/10.1136/jcp.2009.064600>
- [22] Bogaert GA, Heremans B, Renard M, et al. Does preoperative chemotherapy ease the surgical procedure for Wilms tumor. *J Urol.* 2009; 182(4 suppl): 1869-1874. PMID: 19692015. <https://doi.org/10.1016/j.juro.2009.03.022>

- [23] Litten JB, Tomlinson GE. Is preoperative chemotherapy useful for nonmetastatic Wilms' tumor. *Nat Clin Pract Oncol*. 2007; 4(5): 272-273. PMID: 17356534. <https://doi.org/10.1038/nncponc0769>
- [24] Jagt CT, Zuckermann M, Ten KF, et al. Venous-occlusive disease as a complication of preoperative chemotherapy for Wilms tumor: A clinico-pathological analysis. *Pediatr Blood Cancer*. 2009; 53(7): 1211-1215. PMID: 19672975. <https://doi.org/10.1002/pbc.22202>
- [25] Kosmas C, Daladimos T, Athanasopoulos A, et al. Double high-dose chemotherapy and stem cell transplantation in adult Wilms' tumor. *Future Oncol*. 2010; 6(11): 1803-1809. PMID: 21142665. <https://doi.org/10.2217/fon.10.138>
- [26] Tournade MF, Com-Nougue C, de Kraker J, et al. Optimal duration of preoperative therapy in unilateral and nonmetastatic Wilms' tumor in children older than 6 months: results of the Ninth International Society of Pediatric Oncology Wilms' Tumor Trial and Study. *J Clin Oncol*. 2001; 19: 488-500. PMID: 11208843. <https://doi.org/10.1200/JCO.2001.19.2.488>
- [27] Yang Y, Liu K, Qin Y, et al. Preoperative chemotherapy analysis of advanced nephroblastoma in children. *Journal of Practical Cancer*. 2010; 25: 40-42.
- [28] Terenziani M, Spreafico F, Collini P, et al. Adult Wilms tumor: A monoinstitutional experience and a review of the literature. *Cancer*. 2004; 101(2): 289-293. PMID: 15241825. <https://doi.org/10.1002/cncr.20387>
- [29] Xu DS, Chen JL, Huang ZM. *Clinical CT diagnosis*. Guangzhou: Guangdong science and Technology Press; 1998. 268 p.
- [30] Guo YL. *Tumors of the Urinary and Male Genital System*. Beijing: People's Medical Publishing House; 2000. 228-234 p.
- [31] Terenziani M, Spreafico F, Collini P, et al. Adult Wilms' tumor: a monoinstitutional experience and a review of the literature. *Cancer*. 2004; 101: 289-293. PMID: 15241825. <https://doi.org/10.1002/cncr.20387>
- [32] Spreafico F, Bellanin FF. Wilms' tumor: past, present and (possibly) future. *Expert Rev Anticancer Ther*. 2006; 6(2): 249-258. PMID: 16445377. <https://doi.org/10.1586/14737140.6.2.249>
- [33] Terenziani M, Spreafico F, Collini P, et al. Adult Wilms' tumor: a monoinstitutional experience and a review of the literature. *Cancer*. 2004; 101(2): 289. PMID: 15241825. <https://doi.org/10.1002/cncr.20387>
- [34] Zhao JF, Zheng SB, Gao Y, et al. Clinical features of adult nephroblastoma. *Chinese Journal of Urology*. 2008; 29: 303-305.
- [35] Hamilton TE, Ritchey ML, Haase GM, et al. The management of synchronous bilateral Wilms' tumor: a report from the NWTSG. *Ann Surg*. 2011; 253(5): 1004-1010. PMID: 21394016. <https://doi.org/10.1097/SLA.0b013e31821266a0>
- [36] Ritchey ML, Green DM, Thoms PR, et al. Renal failure in Wilms' tumor patients: a report from the National Wilms' Tumor Study Group. *Med Pediatr Oncol*. 1996; 26(2): 75-80. [https://doi.org/10.1002/\(SICI\)1096-911X\(199602\)26:2<75::AID-MP01>3.0.CO;2-R](https://doi.org/10.1002/(SICI)1096-911X(199602)26:2<75::AID-MP01>3.0.CO;2-R)
- [37] Hamilton TE, Ritchey ML, Argani P, et al. Synchronous bilateral Wilms' tumor with complete radiographic response managed without surgical resection: a report from the National Wilms' Tumor Study 4. *J Pediatr Surg*. 2008; 43(11): 1982-1984. PMID: 18970928. <https://doi.org/10.1016/j.jpedsurg.2008.05.037>
- [38] Xu M, Chen QM, Zhu J, et al. Surgical treatment of bilateral nephroblastoma in children. *Chinese Journal of Pediatric Surgery*. 2011; 9(32): 655-657.